Unit 6 Musculoskeletal system

Ms. Randall

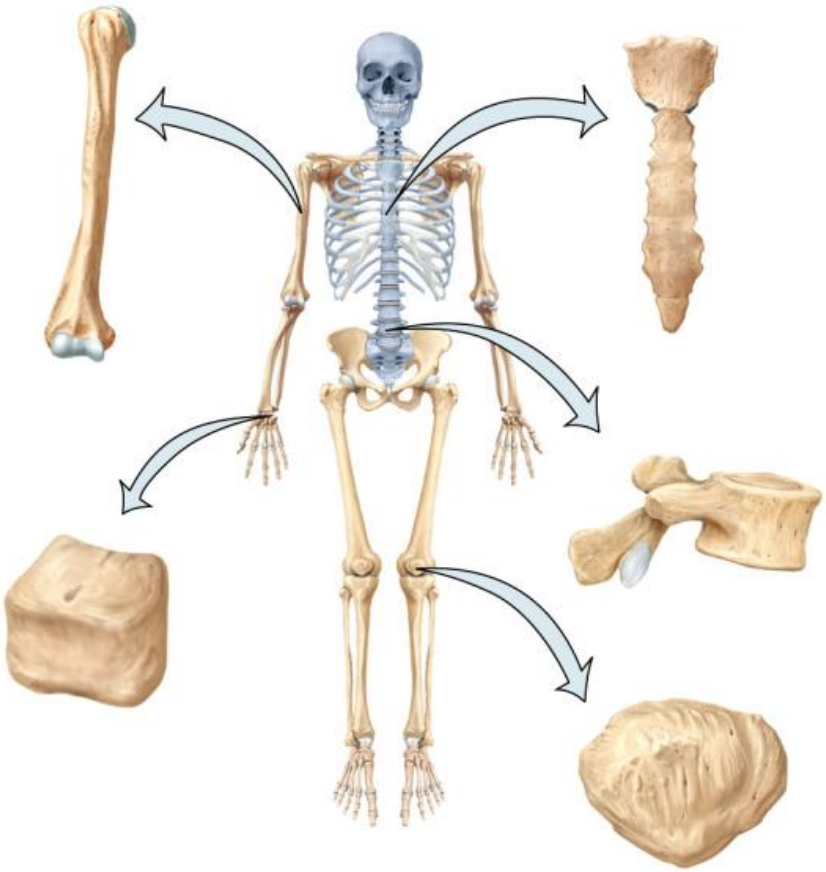

Lesson 1: What are bones?

Objective:

- List and describe the functions of the skeletal system
- Classify bones according to their shapes
- Describe the function of each category of bones

Skeletal system

- Bones of skeleton
  - 206 in adult
  - More in infants and children as some fuse later
- Skeletal muscles
- Joints

- Skeleton divisions
  - Axial - skull bones, ribs, sternum, vertebral column, auditory ossicles, and hyoid bone
  - Appendicular - upper and lower limb bones, and the shoulder and hip girdles

Major Bones of Skeleton

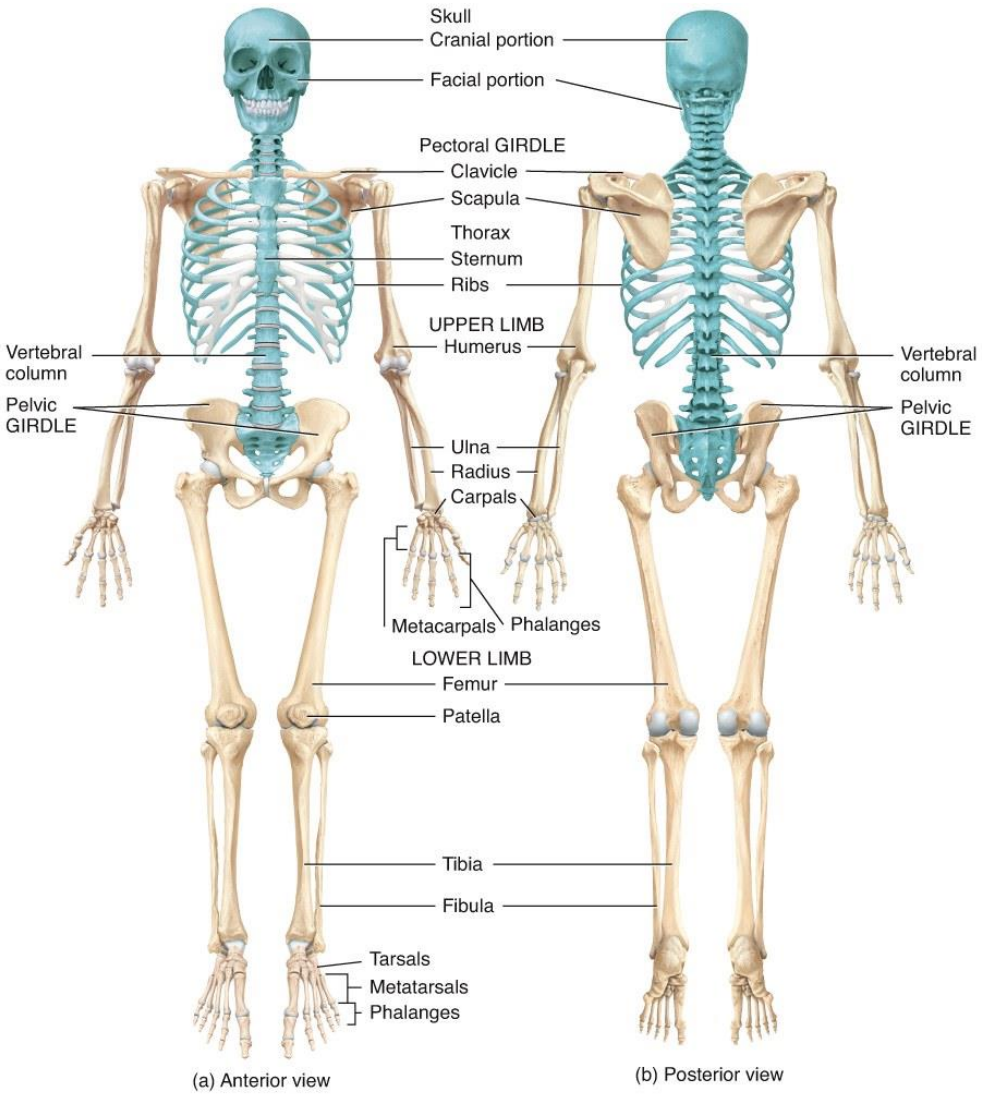

Divisions of Skeleton

TABLE 7.1

The Bones of the Adult Skeletal System

DIVISION OF THE SKELETON	STRUCTURE	NUMBER OF BONES
Axial skeleton	**Skull**	
	Cranium	8
	Face	14
	Hyoid	1
	Auditory ossicles	6
	Vertebral column	26
	Thorax	
	Sternum	1
	Ribs	24
	Number of bones = 80	

DIVISION OF THE SKELETON	STRUCTURE	NUMBER OF BONES
Appendicular skeleton	**Pectoral (shoulder) girdles**	
	Clavicle	2
	Scapula	2
	Upper limbs	
	Humerus	2
	Ulna	2
	Radius	2
	Carpals	16
	Metacarpals	10
	Phalanges	28
	Pelvic (hip) girdle	
	Hip, pelvic, or coxal bone	2
	Lower limbs	
	Femur	2
	Patella	2
	Fibula	2
	Tibia	2
	Tarsals	14
	Metatarsals	10
	Phalanges	28
	Number of bones = 126	

Total bones in an adult skeleton = 206

Bones are composed of several different tissues working together

- Osseous tissue
- Cartilage
- Dense connective tissue
- Epithelium
- Adipose tissue
- Nervous tissue

All of the bones and their cartilages, along with ligaments and tendons, constitute the skeletal system

Skeletal System Functions

- Supports soft tissues and provides attachment points for tendons of skeletal muscles
- Protects the most important internal organs
- Assists in movement by acting as levers for skeletal muscles
- Osseous tissue stores and releases minerals, particularly calcium and phosphorus
- Red marrow within bones produces blood cells
- Yellow marrow within bones stores triglycerides, a source of potential energy

Classification of Bones

Long bones

- Greater length than width
- Long bones function as levers; they move when muscles contract.

Short bones

- Nearly equal length and width
- Short bones provide stability and support as well as some limited motion

Flat bones

- Thin
- Flat bones serve as points of attachment for muscles and often protect internal organs

Classification of Bones

Irregular bones

- Complex shapes
- the vertebrae that support the spinal cord and protect it from compressive forces

Sesamoid bones

- Shaped like a sesame seed
- typically found in tendons associated with the feet, hands, and knees

Classification of Bones

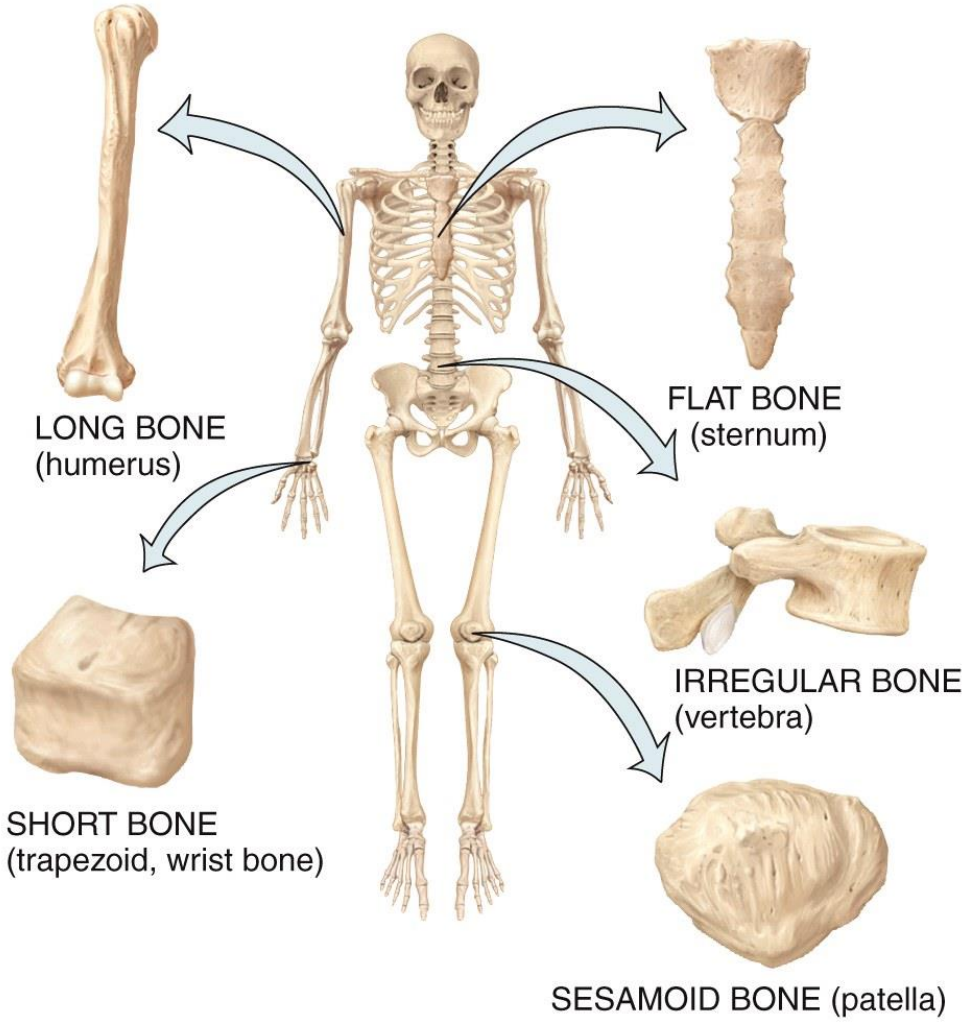

Bone Classifications

Bone classification	Features	Function(s)	Examples
Long	Cylinder-like shape, longer than it is wide	Leverage	Femur, tibia, fibula, metatarsals, humerus, ulna, radius, metacarpals, phalanges
Short	Cube-like shape, approximately equal in length, width, and thickness	Provide stability, support, while allowing for some motion	Carpals, tarsals
Flat	Thin and curved	Points of attachment for muscles; protectors of internal organs	Sternum, ribs, scapulae, cranial bones
Irregular	Complex shape	Protect internal organs	Vertebrae, facial bones
Sesamoid	Small and round; embedded in tendons	Protect tendons from compressive forces	Patellae

Lesson 2 : How are bones structured?

Objective:

- Identify the anatomical features of a bone
- Define and list examples of bone markings
- Compare and contrast compact and spongy bone
- Identify the structures that compose compact and spongy bone
- Describe how bones are nourished and innervated

Long Bone Anatomy

- Regions of a long bone
  - Diaphysis [the shaft]
  - Medullary cavity [inside shaft]
  - 2 Epiphyses [proximal and distal]
  - 2 Metaphyses [join diaphysis and epiphysis with epiphyseal plate, or line once growth stops]
- Surface tissues
  - Endosteum
  - Periosteum
  - Articular cartilage

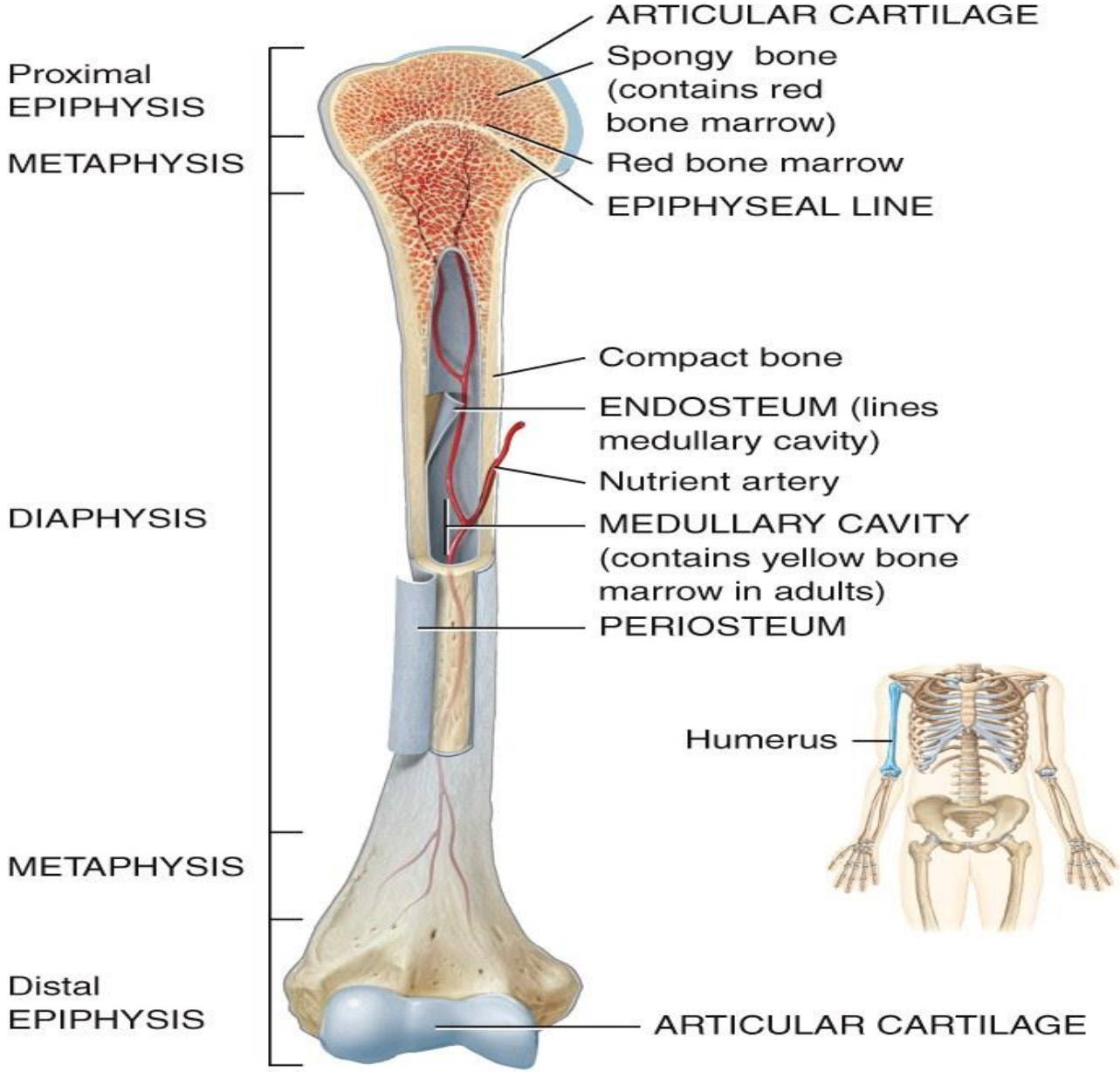

(a) Partially sectioned humerus (arm bone)

Osseous Tissue

- Extracellular matrix of connective tissue
  - Water
  - Collagen fibers - gives property of flexibility and tensile strength
  - Crystallized mineral salts of hydroxyapatites - gives property of hardness

Four principal types of cells

- Osteogenic - undifferentiated, give rise to osteoblasts by cell division
- Osteoblasts - bone-building by calcification
- Osteocytes - maintain daily tissue activities
- Osteoclasts - bone-destroying by resorption

Cells in Osseous Tissue

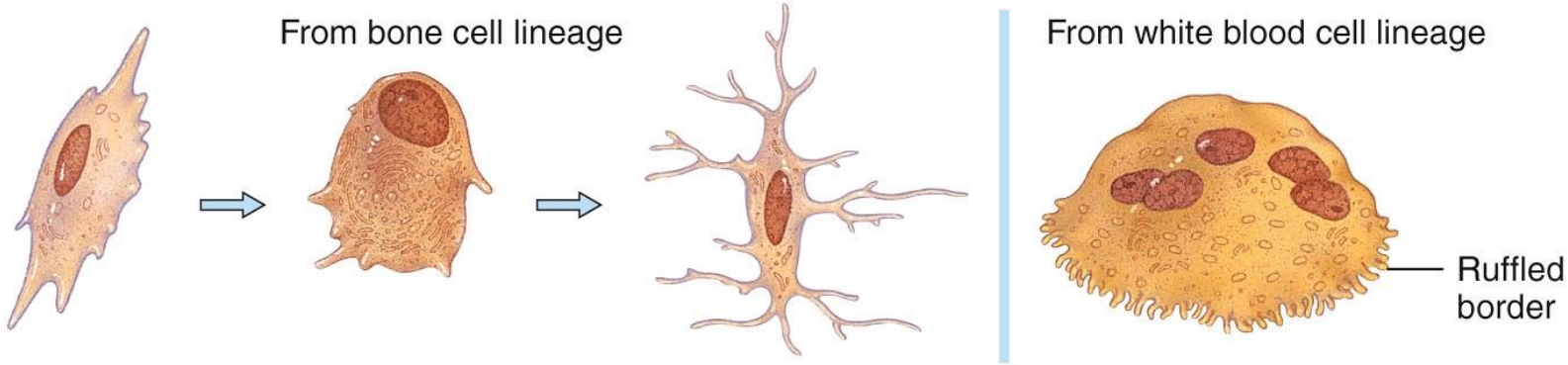

Osteogenic cell (develops into an osteoblast)

Osteoblast (forms bone extracellular matrix)

Osteocyte (maintains bone tissue)

Osteoclast (functions in resorption, the breakdown of bone extracellular matrix)

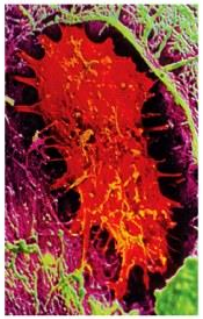

SEM 1160x

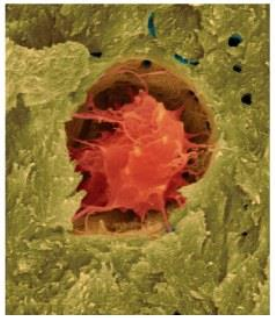

SEM 1160x

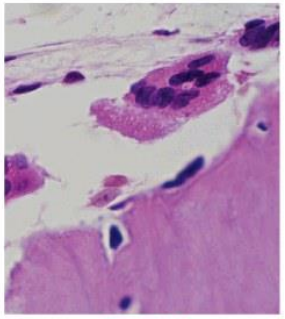

SEM 5626x

Types of Osseous Tissue

- Compact bone
  - Forms external layer of all bones and comprises most of the diaphysis of long bones
- Spongy bone
  - Forms interior of short, flat, irregular, and sesamoid bones, most of epiphysis of long bones, and narrow rim around medullary cavity of long bones

Compact Bone Structure

- Osteons form repeating structural units aligned in same direction, with few spaces
  - Central canal with blood and lymph vessels and nerves
  - Concentric lamellae of extracellular matrix
  - Lacunae between lamellae with osteocytes
  - Canaliculi connect lacunae and central canal
- Interstitial lamellae between osteons
- Circumferential lamellae encircle bone
- Perforating canals penetrate transverse through osteons from periosteum

Compact Bone Structure

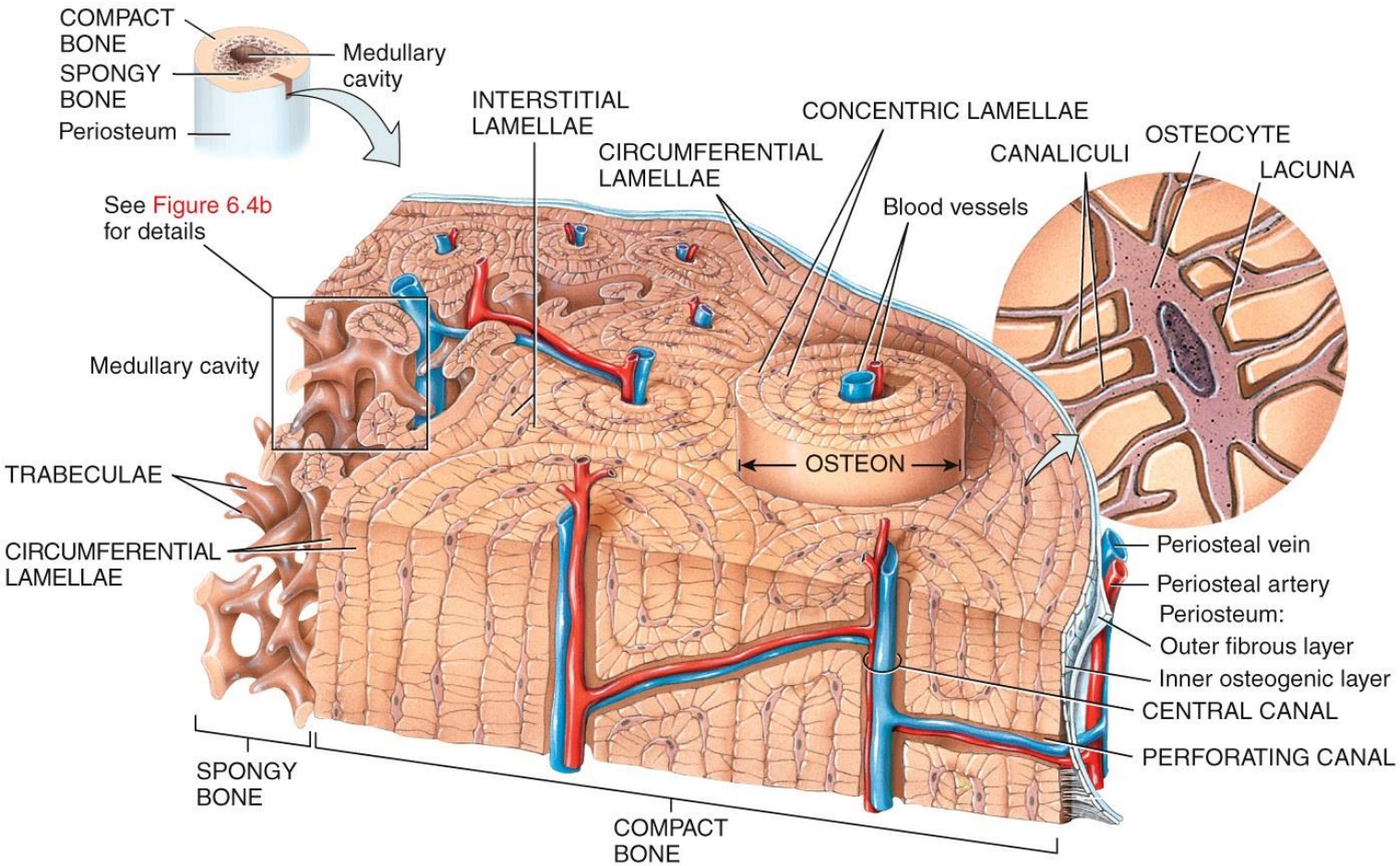

(a) Osteons (haversian systems) in compact bone and trabeculae in spongy bone

Spongy Bone Structure

- Trabeculae form irregular lattice of lamellae extracellular matrix oriented in many directions
  - Lacunae with osteocytes
  - Canaliculi connect lacunae
  - Osteoblasts and osteoclasts under periosteum
- Spaces between trabeculae
  - Filled with red bone marrow
  - Site of blood cell production in adults (hemopoiesis)

Spongy Bone Structure

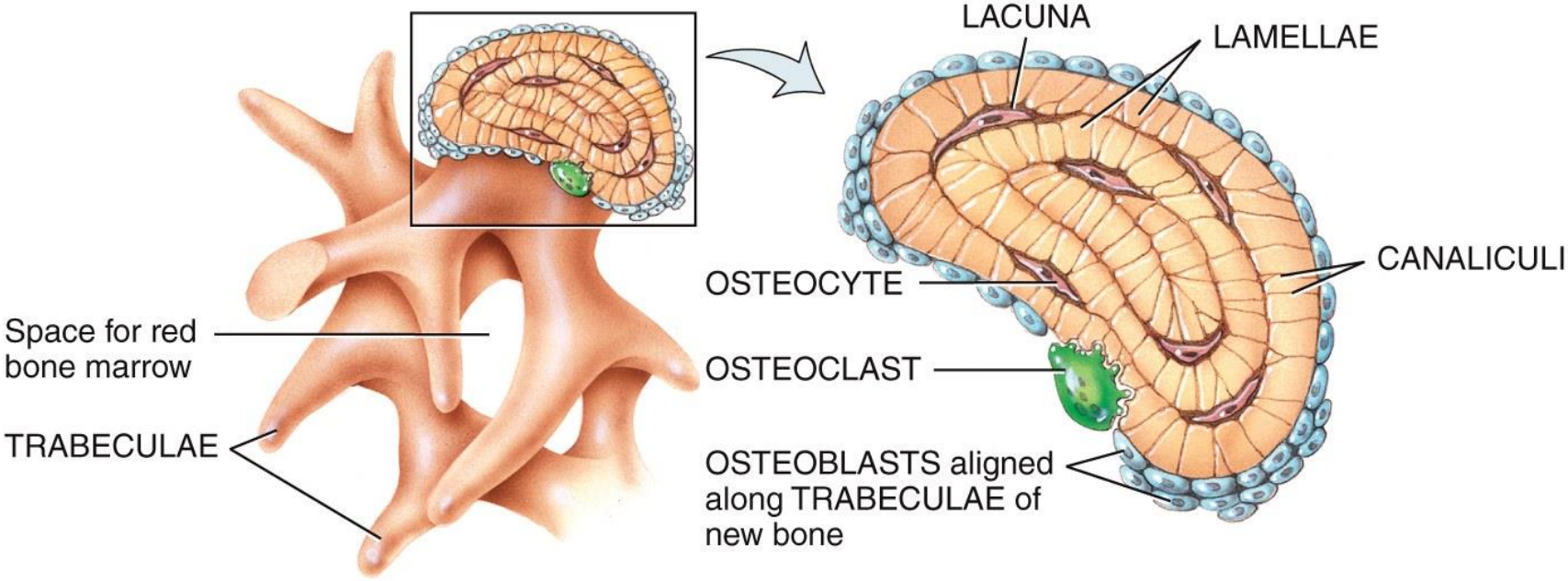

(b) Enlarged aspect of spongy bone trabeculae

(c) Details of a section of a trabecula

Blood and Nerve Supply to Bones

- Highly vascular with blood vessels passing into bones from periosteal artery
  - Nutrient foramen - leads to perforating canal through periosteum
  - Nutrient artery and vein - diaphysis and parts of metaphysis
  - Metaphyseal artery and vein
  - Epiphyseal artery and vein
- Sensory nerves accompany blood vessels

Blood Supply to Bones

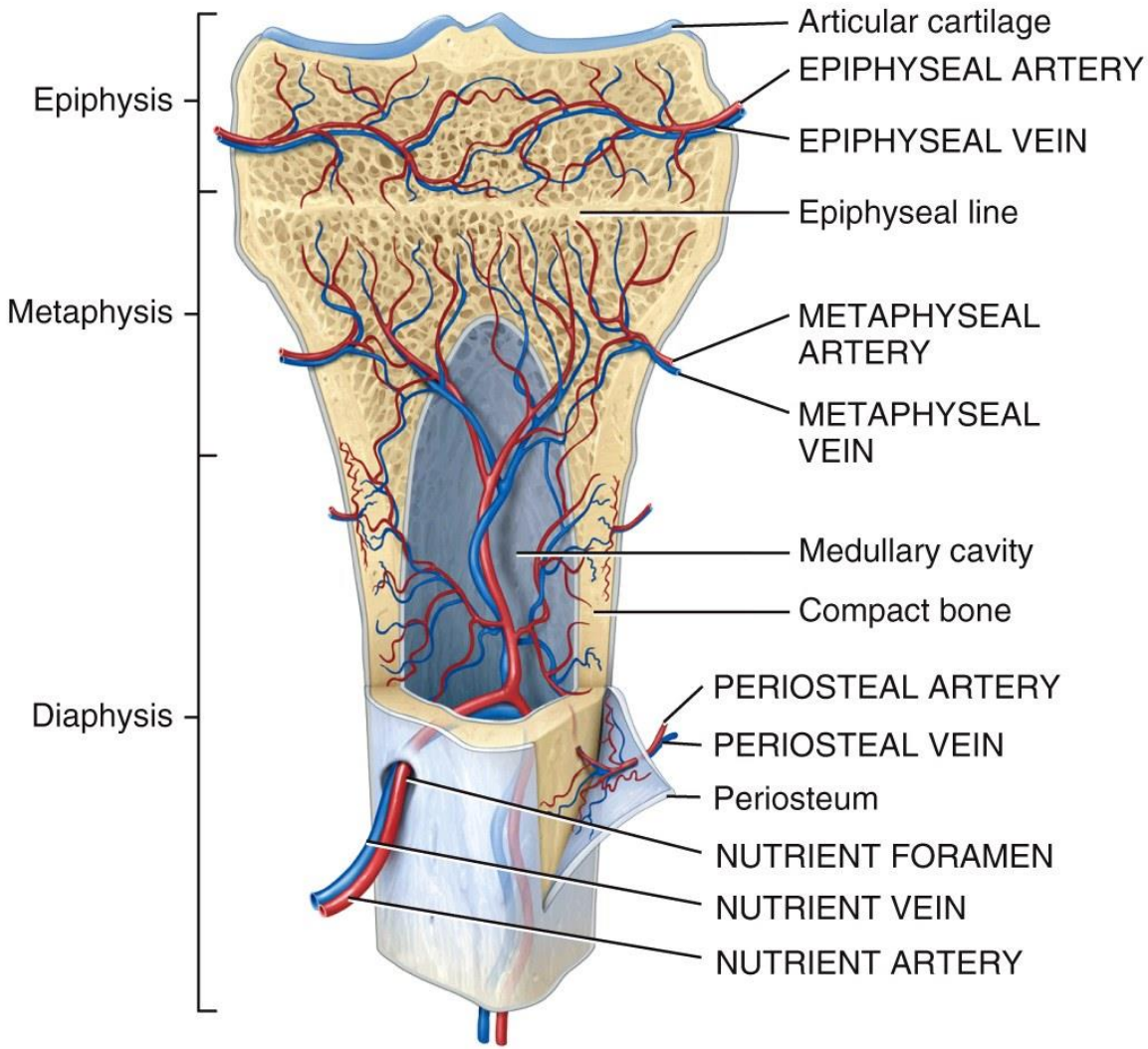

Partially sectioned tibia (shin bone)

Bone Surface Markings

- In addition to names, bones have unique structural features that serve as anatomical landmarks, and also have various functional roles
- Two major types of surface markings
  - Depressions and openings - usually allow passage of blood vessels and nerves or help form joints
  - Processes - projections that either help form joints or serve as attachment points for ligaments and tendons

Lesson 3: How are bones formed and repaired?

Objective:

- List the steps of intramembranous ossification
- Compare and contrast the processes of modeling and remodeling
- Explain the process of calcium homeostasis

Types of Bone Formation

- Ossification
  - Initial formation of bones before birth
  - Growth of bones until adult size reached
  - Remodeling and repair of bones
- Intramembranous ossification
  - Bone develops directly within sheet-like mesenchyme layers
  - Flat bones of skull, mandible, and clavicle
- Endochondral ossification
  - Most bones in body form within hyaline cartilage that develops from mesenchyme

Growth in Length and Width

- Epiphyseal plate involved in growth in length
  - Throughout childhood and adolescence long bones grow
  - Growth of cartilage on epiphyseal side
  - Replacement of cartilage on diaphysis side
  - Epiphyseal line remains when growth has stopped

- Bone grows in diameter as osteoblasts in periosteum secrete extracellular matrix to form new lamellae while osteoclasts of endosteum enlarge medullary cavity

Growth in Length and Width

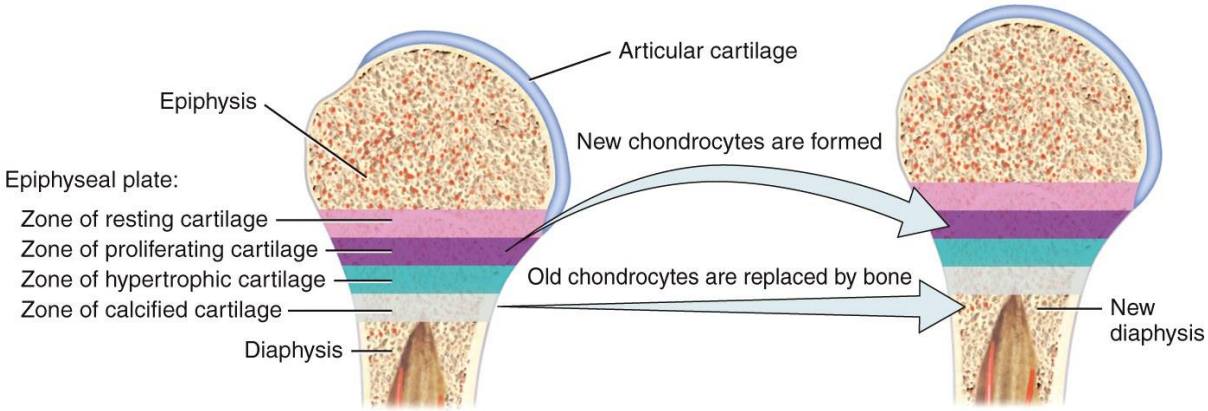

(c) Lengthwise growth of bone at epiphyseal plate

(a) Radiograph showing epiphyseal plate of femur of a 3-year-old

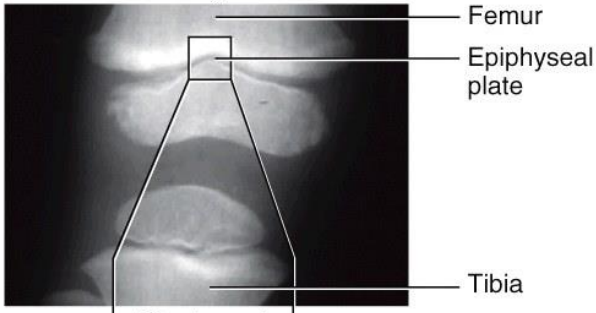

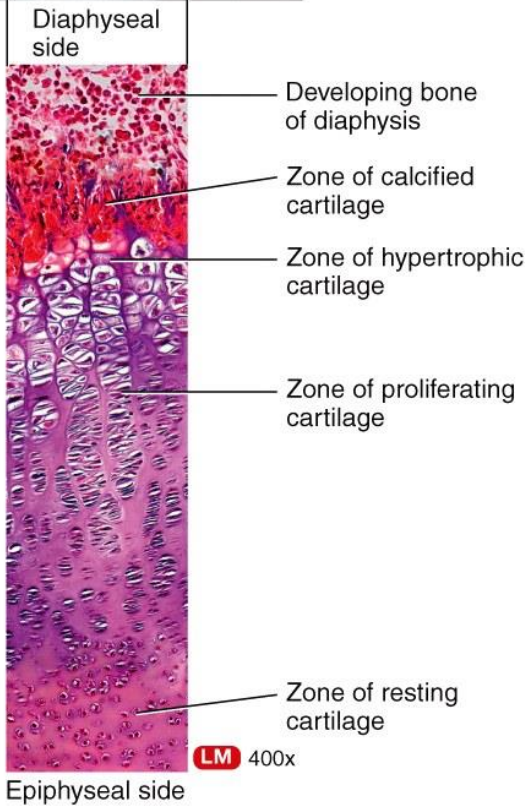

(b) Histology of epiphyseal plate

(top) The Bergman Collection; (bottom) Mark Nielsen

Bone Remodeling

- Continues throughout life
  - Osteoclasts destroy old osseous tissue
  - Osteoblasts rebuild it
- Renews osseous tissue before deterioration occurs
- Heals injured bones
- Redistributes bone extracellular matrix along lines of mechanical stress

Bone Remodeling

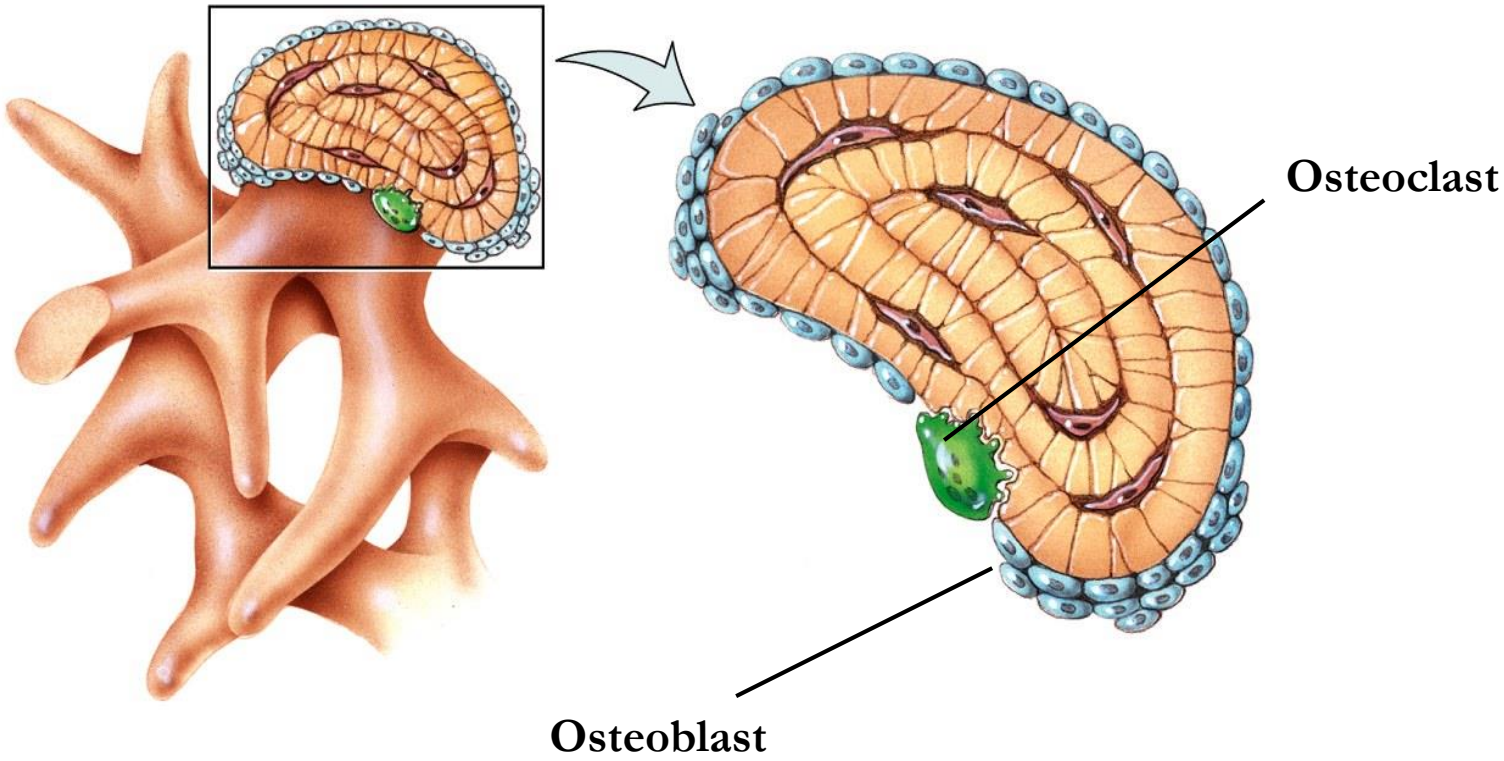

Factors Influencing Bone Growth and Remodeling

- Growth and maintenance of bones depends on adequate nutrition (energy, calcium, many vitamins)
- Hormones
  - Growth hormone and IGF's stimulate bone growth
  - Thyroid hormone and insulin also promote bone growth
  - Sex steroids (estrogen and testosterone) stimulate bone growth in gender specific patterns
  - Epiphyseal plate closure results from higher levels of estrogens

Bone as Reservoir for Calcium in Blood

- Parathyroid hormone secreted by the parathyroid gland increases blood calcium level
  - Stimulates osteoclasts
- Vitamin D enhances absorption of calcium from food, thus raises blood calcium level
- Calcitonin from thyroid gland has the potential to decrease blood calcium level
  - Inhibits osteoclast activity
  - Stimulates osteoblasts

Lesson 4 : Classification of Joints

Objective:

- Discuss both functional and structural classifications for body joints.
- Describe the characteristic features for fibrous, cartilaginous, and synovial joints and give examples of each.

An articulation, or joint

- An articulation, or joint, is the area where two or more bones meet, or where bone and cartilage, or bone and teeth meet
- When we say one bone articulates with another bone, we mean that the bones form a joint
- Most body movements of the body occur at joints
- Joints are classified structurally or functionally

Structural Classification of Joints

- Based on the anatomical characteristics
  - Presence or absence of a synovial cavity
  - Type of connective tissue binding the bones together
- Three structural types
  - Fibrous
    - Held together by dense connective tissue; no synovial cavity
  - Cartilaginous
    - Held together by cartilage; no synovial cavity
  - Synovial
    - Held together by dense connective tissue of an articular capsule and possess a synovial cavity

Functional Classification of Joints

- Based on degree of movement permitted
- Three functional types
  - **Synarthrosis** (synarthroses, pleural)
    - Immovable
  - **Amphiarthosis** (amphiarthroses, pleural)
    - Slightly movable
  - **Diarthrosis** (diarthroses, pleural)
    - Freely movable

- A **uniaxial diarthrosis**,, is a joint that only allows for movement within a single anatomical plane. J
- Joints that allow for movements in two planes are **biaxial joints**,
- A **multiaxial joint**, such as the shoulder or hip joint, allows for three planes of motions.

- Each structurally classified joint will also be classified by function

Fibrous Joints

- Articulating bones are held very closely together by dense connective tissue and permit little to no movement
- Three types of fibrous joints
  - Suture
  - Syndesmosis and gomphosis
  - Interosseous membrane

Fibrous Joints: Example Suture

- Functionally classified as synarthroses in adults, but in infants and children they are amphiarthroses

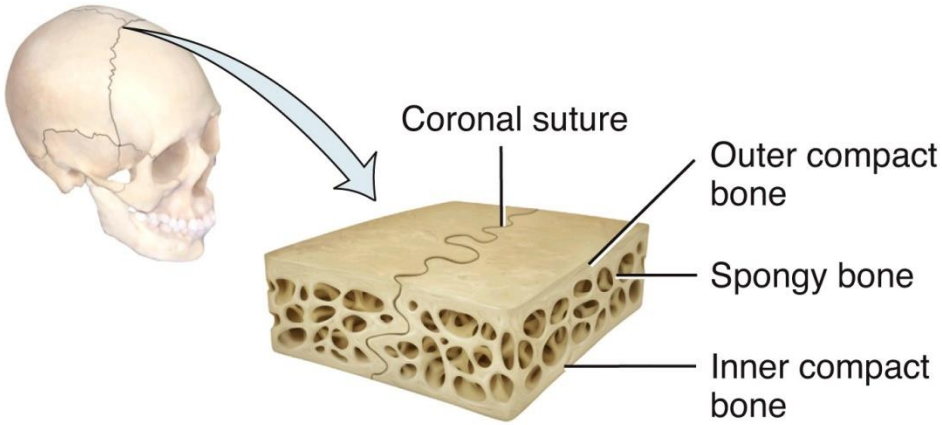

(a) Suture between skull bones

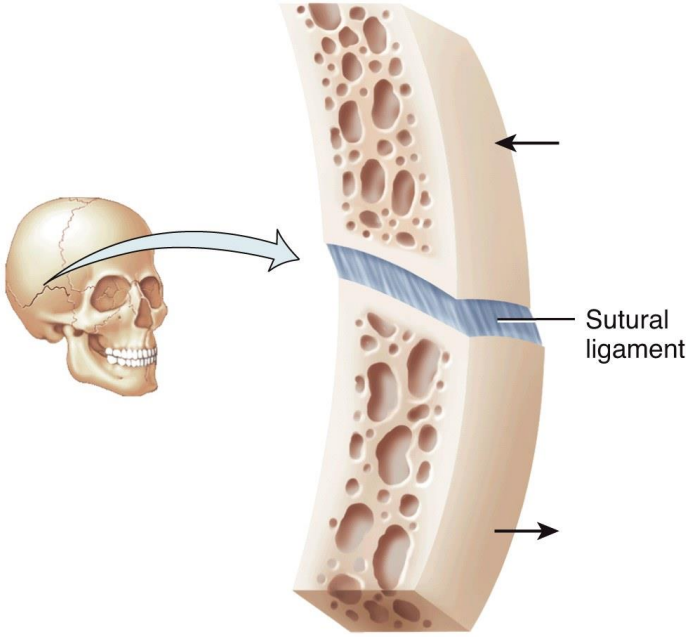

(b) Slight movement at suture

Fibrous Joints: Example Syndesmosis

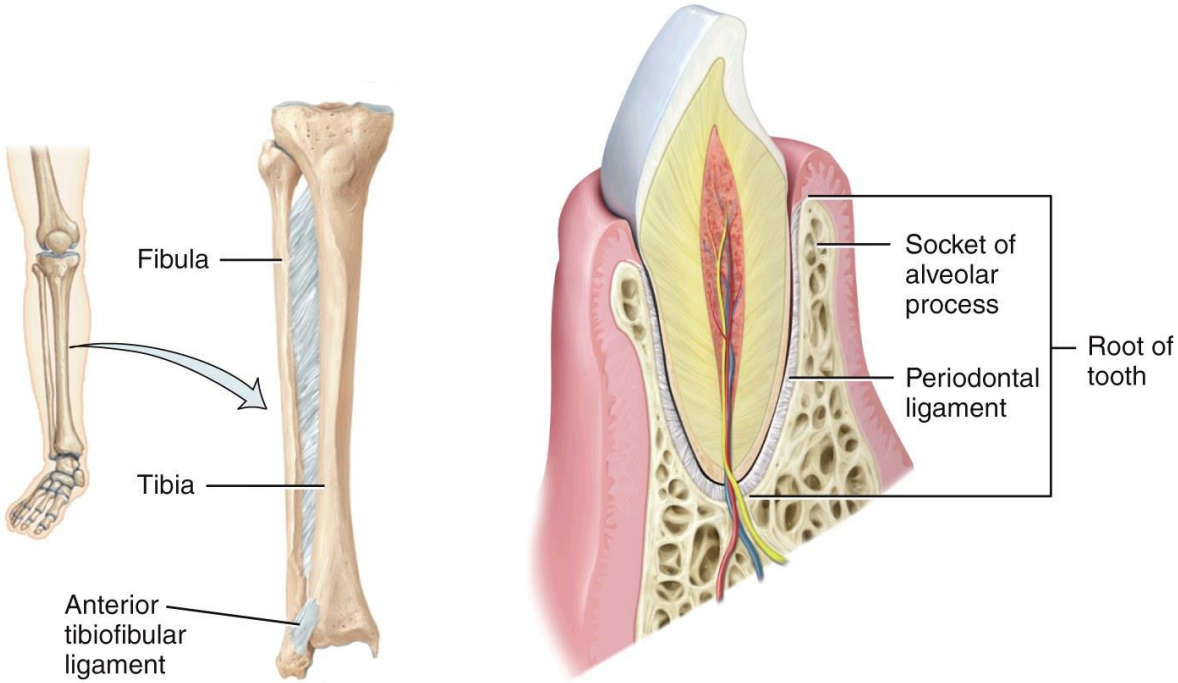

Syndesmosis between tibia and fibula at distal tibiofibular joint

Syndesmosis between tooth and socket of alveolar process (gomphosis)

(c) Syndesmosis

- Functionally classified as amphiarthroses, except for gomphoses of teeth that are synarthroses

Fibrous Joints: Example Interosseous Membrane

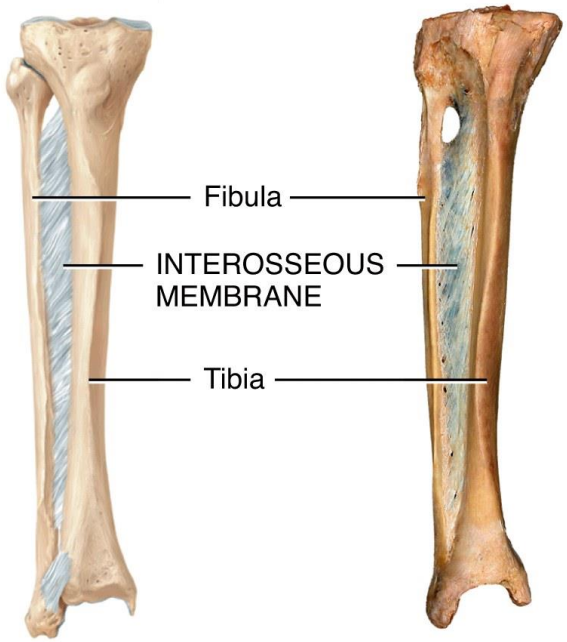

(d) Interosseous membrane between diaphyses of tibia and fibula

- Functionally classified as amphiarthroses

Cartilaginous Joints

- Articulating bones are tightly connected by hyaline or fibrocartilage tissue
- Two types of cartilaginous joints
  - Synchondrosis
  - Symphysis

Cartilaginous Joints: Example Synchondrosis

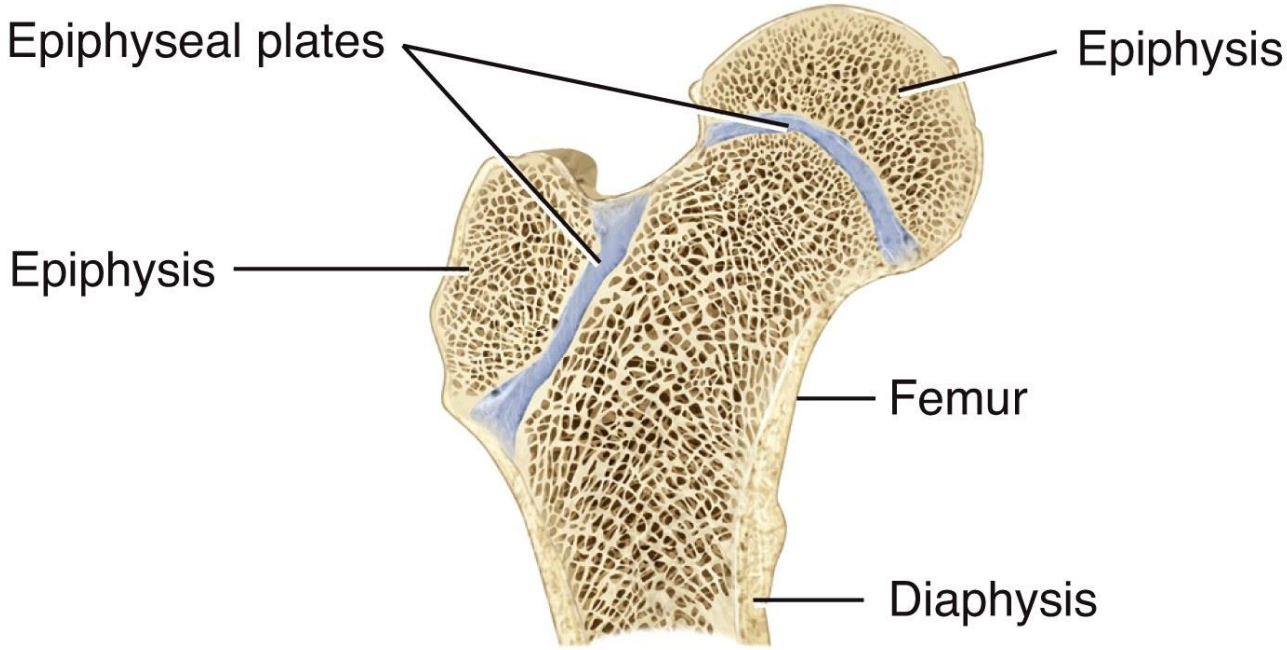

(a) Synchondrosis

- Functionally classified as synarthroses

Cartilaginous Joints: Example Symphysis

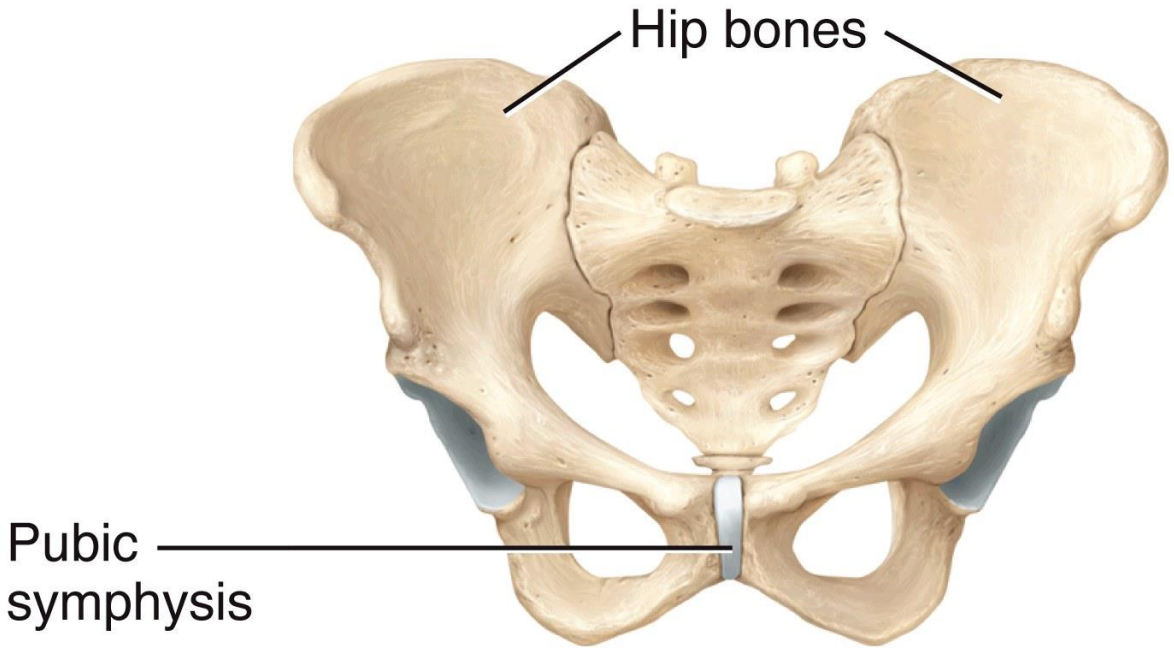

(b) Symphysis

- Functionally classified as amphiarthroses

Synovial Joint Cavity

- All synovial joints have a synovial cavity
- Allows the joint to function as a diarthrosis
- Distinguishing structures of synovial joint
  - Articular hyaline cartilage
    - Reduces friction between bones
    - Helps absorb shock
  - Articular capsule
  - Synovial fluid
- Accessory structures
  - Ligaments and articular menisci
  - Bursae and tendon sheaths

Synovial Fluid

- Forms a thin film over the surface of articular joint structures within the capsule
- Functions
  - Reduce friction by lubrication
  - Absorb shock
  - Supply oxygen and nutrients to avascular articular cartilage tissue of joint
  - Remove wastes
  - Phagocytic cells remove microbes and debris from normal wear and tear of joint

Categories of Synovial Joints

- Shapes of articulating surfaces within synovial joint capsule allow variety of movements
- Major categories
  - Plane joint
  - Hinge joint
  - Pivot joint
  - Condyloid joint
  - Saddle joint
  - Ball-and-socket joint

Synovial Joint: Plane

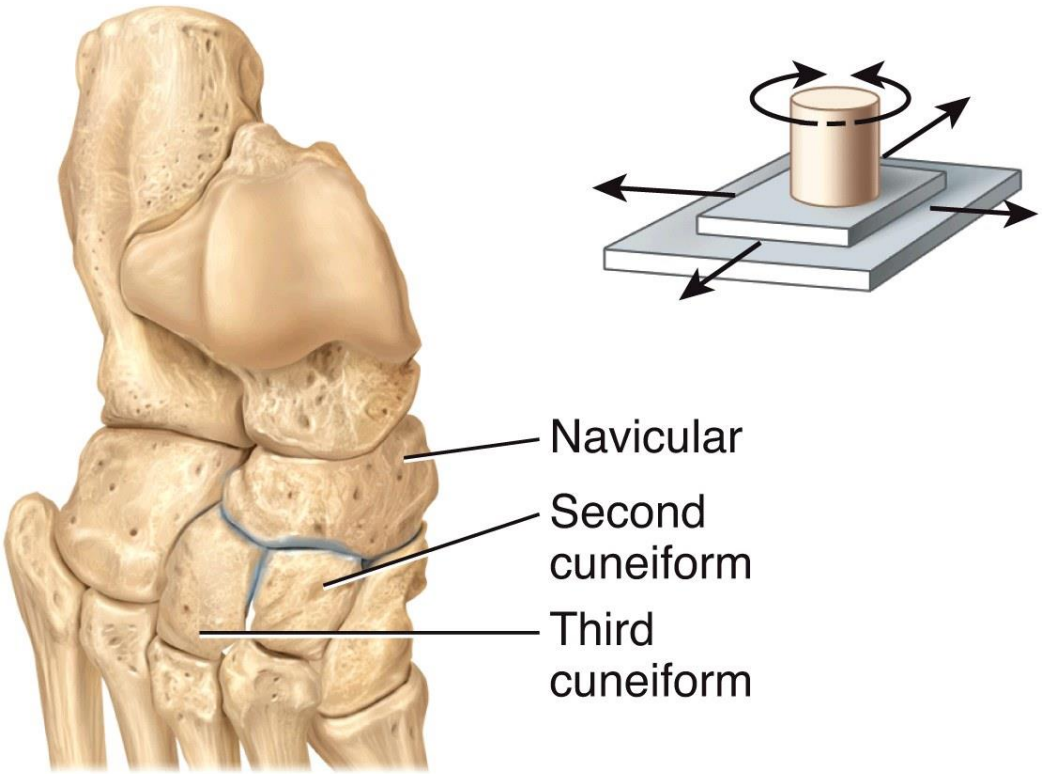

(a) Plane joint between navicular and second and third cuneiforms of tarsus in foot

Synovial Joint: Hinge

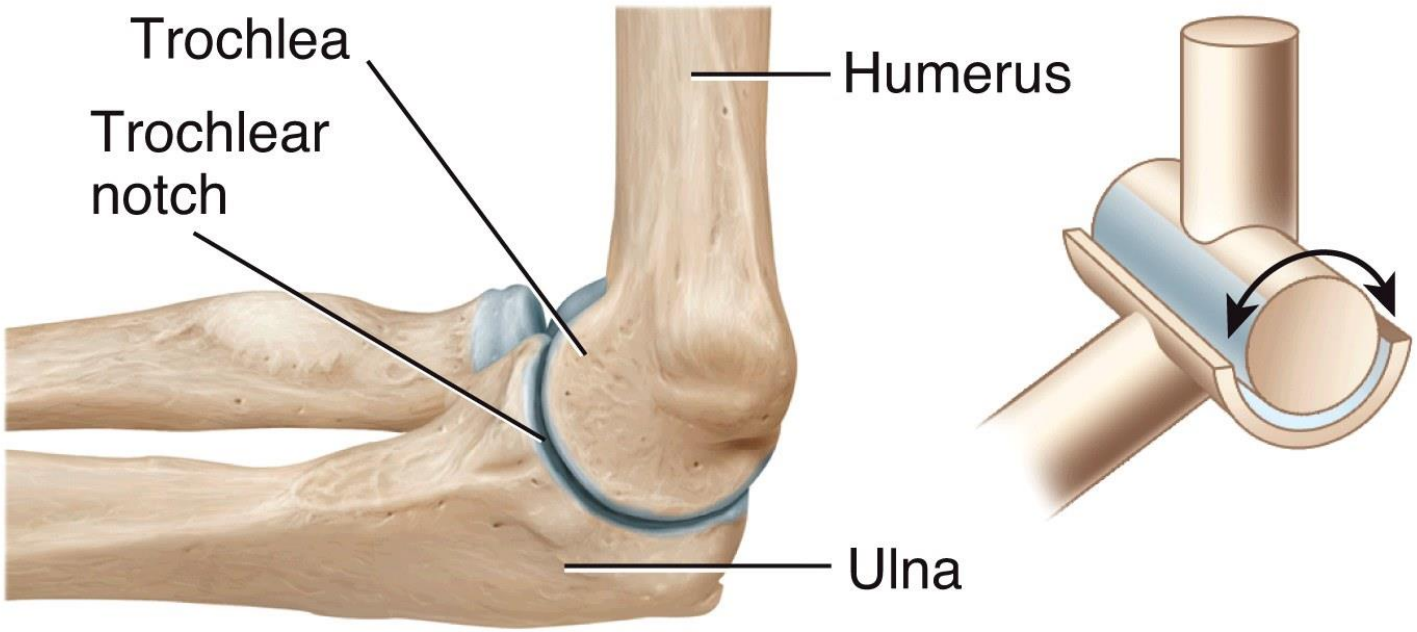

(b) Hinge joint between trochlea of humerus and trochlear notch of ulna at elbow

Synovial Joint: Pivot

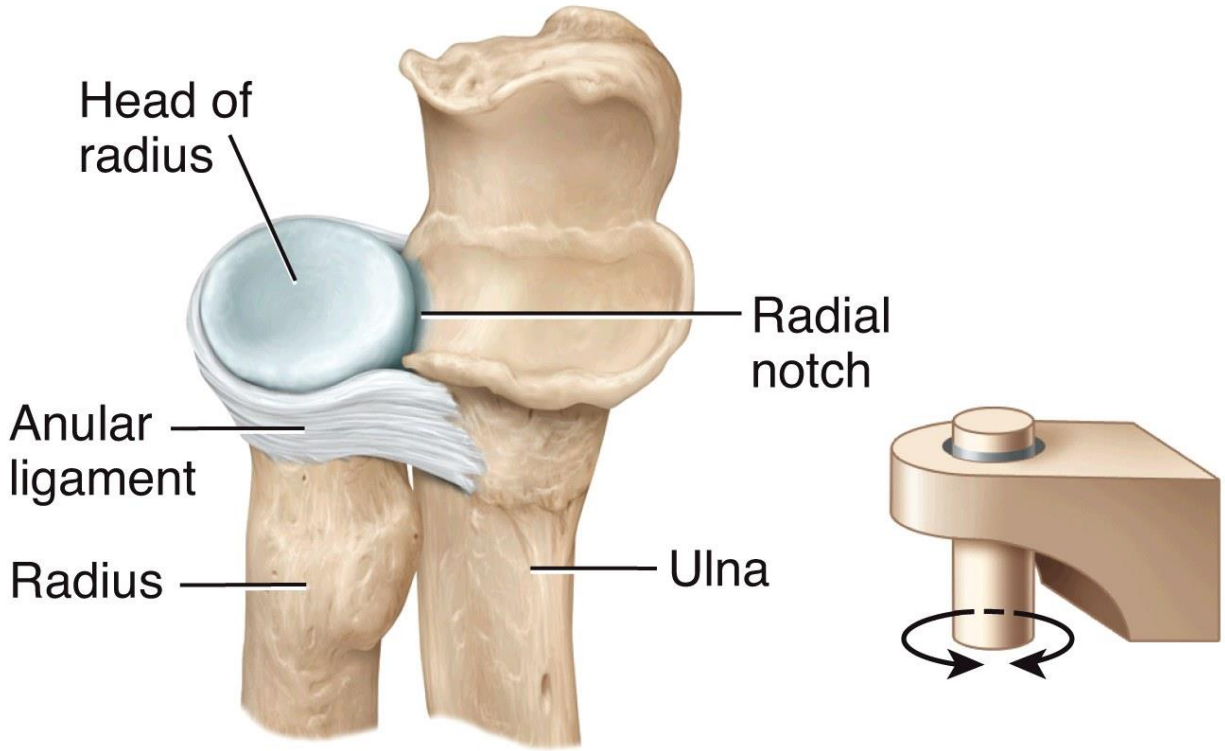

(c) Pivot joint between head of radius and radial notch of ulna

Synovial Joint: Condyloid

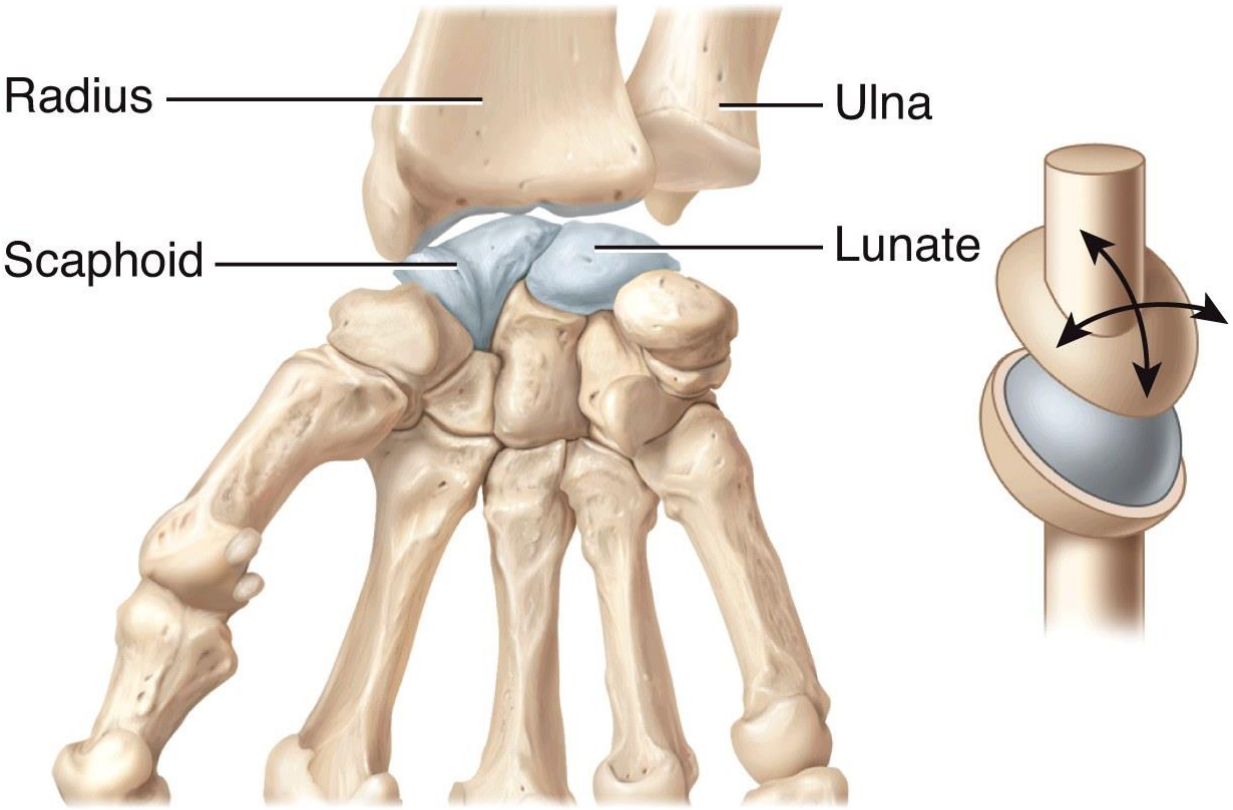

(d) Condyloid joint between radius and scaphoid and lunate bones of wrist

Synovial Joint: Saddle

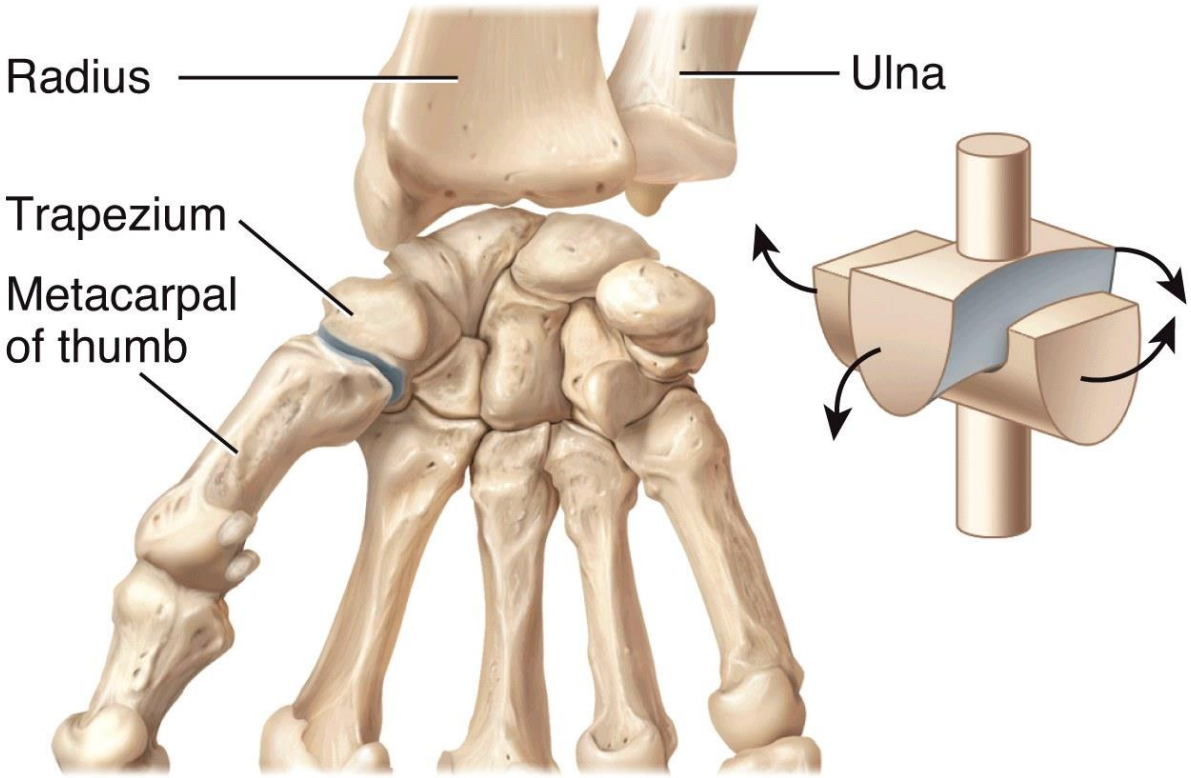

(e) Saddle joint between trapezium of wrist and metacarpal of thumb

Synovial Joint: Ball-and-Socket

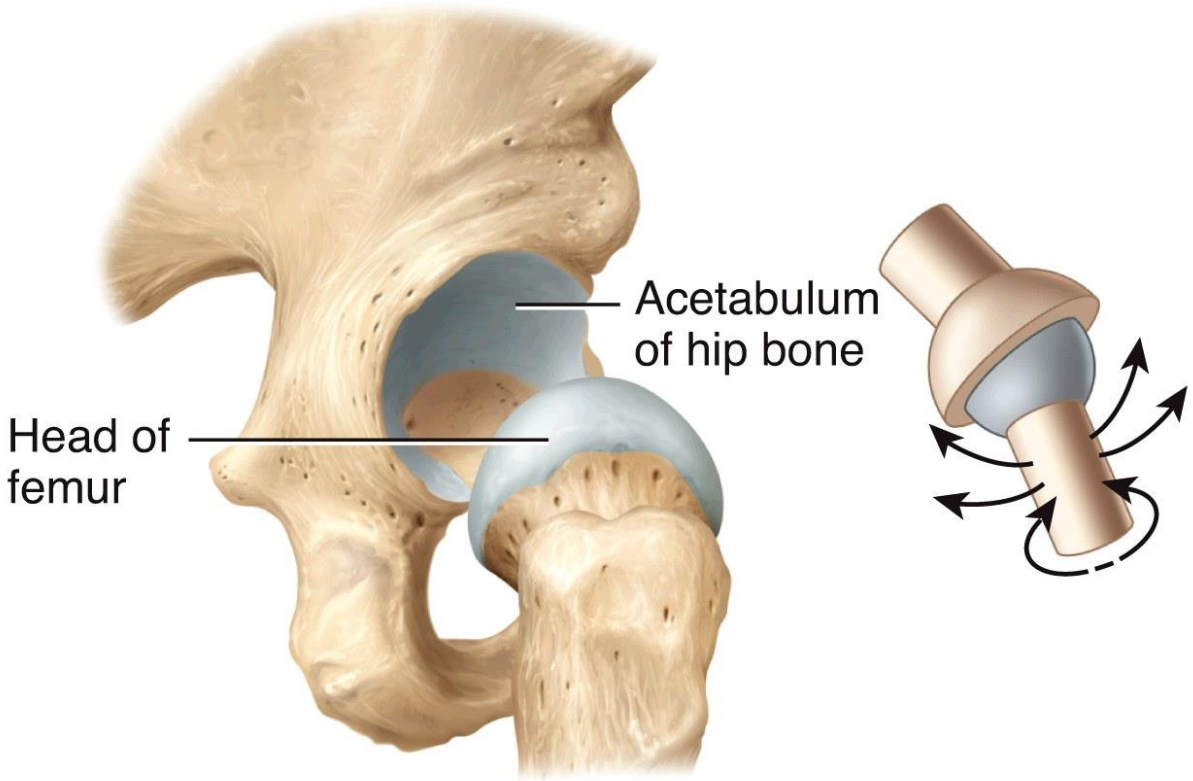

(f) Ball-and-socket joint between head of femur and acetabulum of hip bone

Major Synovial Joints of Body: Shoulder, Elbow, Hip, and Knee

Lesson 5: Skeletal Muscle

Objective:

- Describe the function of skeletal muscles
- Describe the layers of connective tissues packaging skeletal muscle
- Explain how muscles work with tendons to move the body
- Identify areas of the skeletal muscle fibers

Functions of Muscle Tissue

- Produces body movements
  - Integrated function of skeletal muscles with bones and joints
- Stabilizes body positions
  - Skeletal muscle contractions without movement
- Moves substances within the body
  - All three kinds of muscles as part of different organ systems
- Generates heat
  - Involuntary shivering of skeletal muscle helps maintain temperature homeostasis

Special Properties of Muscle Tissue

- Electrical excitability
  - Produce electrical action potentials (impulses) in response to certain stimuli
  - Shared property with neurons
- Contractility
  - Ability to shorten forcefully when stimulated, generating tension
- Extensibility
  - Ability to stretch within limits without being damaged
- Elasticity
  - Ability to return to original length after contraction or extension

Skeletal Muscle as an Organ

- Organ level of organization
  - Different types of tissues function together
- Skeletal muscle tissue
  - Individual cells are called muscle fibers
  - Each skeletal muscle organ composed of hundreds to thousands of muscle fibers
- Connective tissue
  - Surrounds and protects skeletal muscle tissue
- Nerve and blood supply
  - Organ is well supplied with nerves and blood vessels

Skeletal Muscle as an Organ

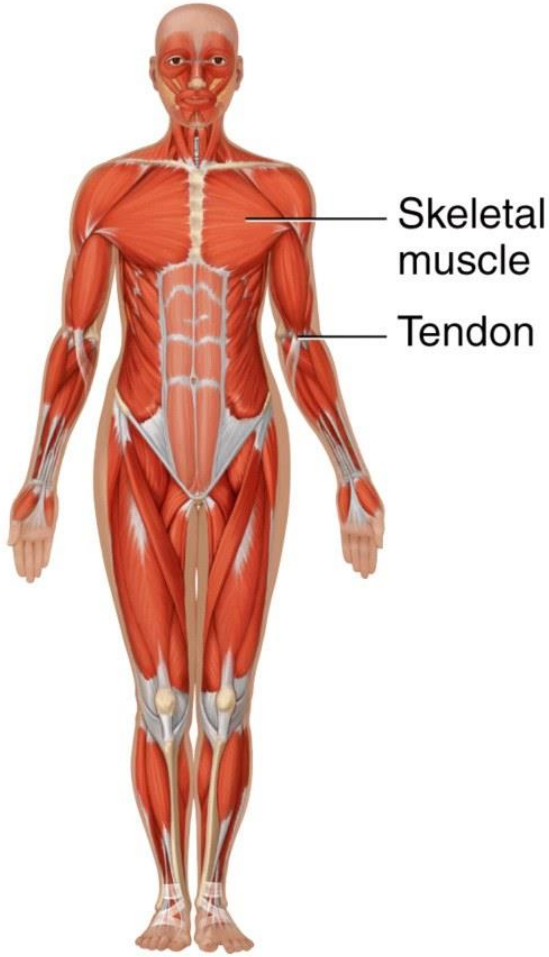

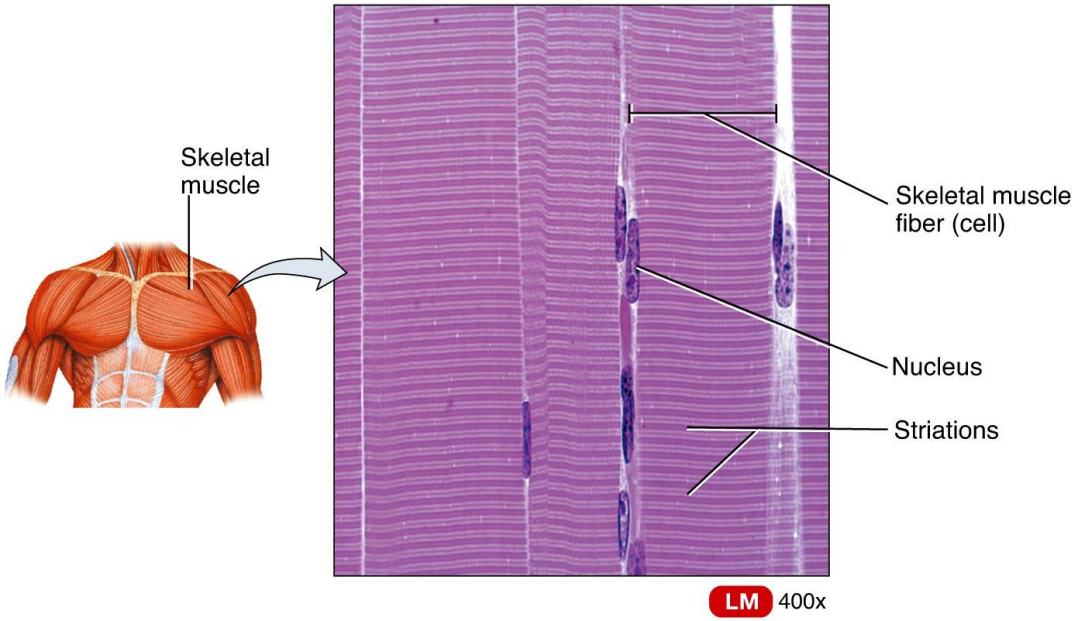

Longitudinal section of skeletal muscle tissue

Connective Tissues of Muscle

- Hypodermis
  - Areolar and adipose tissue
  - Separates muscle from skin, insulates and protects
- Fascia
  - Dense connective tissue sheet
  - Unites muscles with similar functions, carries nerves and vessels, and fills spaces between muscles
- Three layers of connective tissue in organ
  - Protect and strengthen skeletal muscle fibers
- Tendon or aponeurosis
  - Rope-like or broad flat extension of connective tissue beyond muscle fibers for attachment of muscle organ

Three Layers of Connective Tissues

- Epimysium
  - Dense connective tissue, outermost layer
  - Encircles entire muscle organ
- Perimysium
  - Dense, irregular connective tissue
  - Surrounds bundles of muscle fibers called fascicles
  - Each fascicle contains ten to one hundred muscle fibers (cells)
- Endomysium
  - Thin sheath of areolar connective tissue
  - Separates each muscle fiber within fascicle

Three Lay

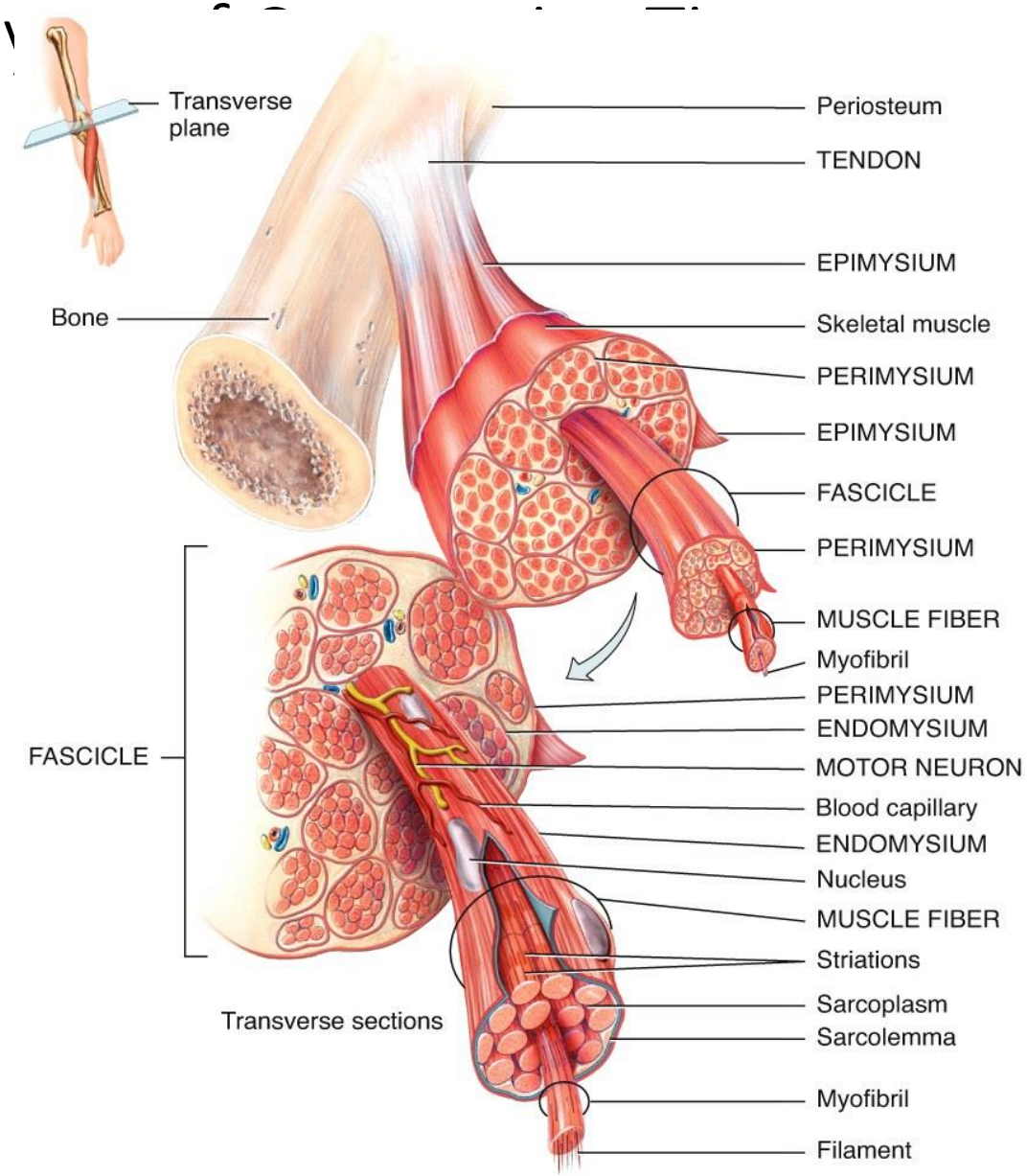

Connective Tissue Attaches Muscle

- Tendon
  - Rope-like extension of three connective tissue layers
  - Attaches muscle directly to periosteum of a bone
  - Example: Achilles tendon attaches gastrocnemius muscle of calf to calcaneus of tarsus
- Aponeurosis
  - Broad, flat sheet extension of three connective tissue layers
  - Attaches muscle to another muscle or bone

Connective Tissue Attaches Muscle

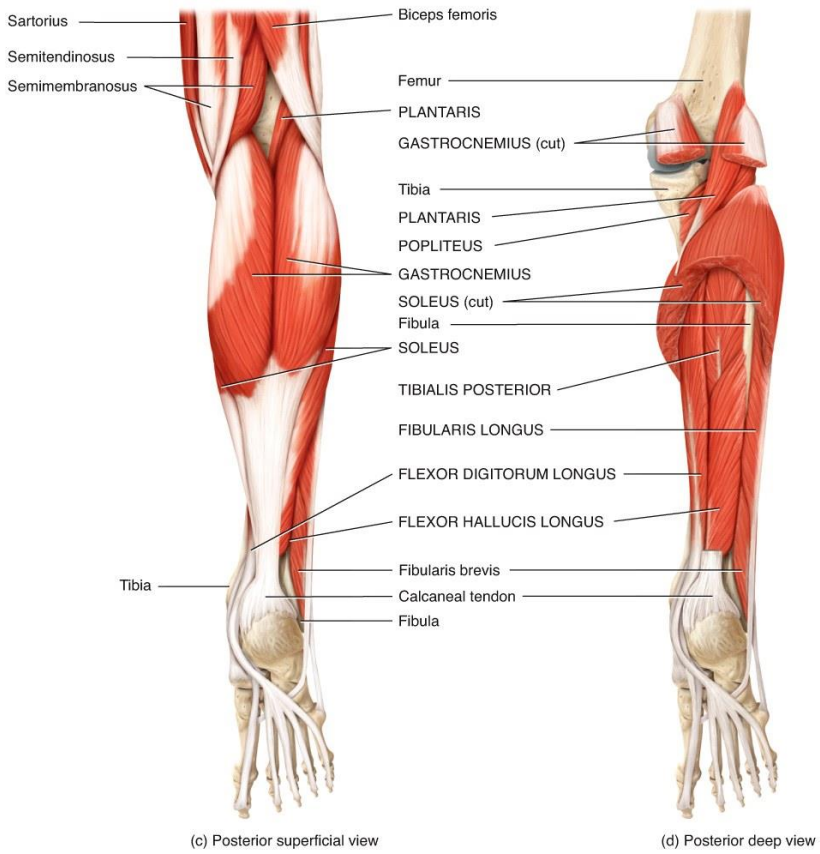

(c) Posterior superficial view (d) Posterior deep view

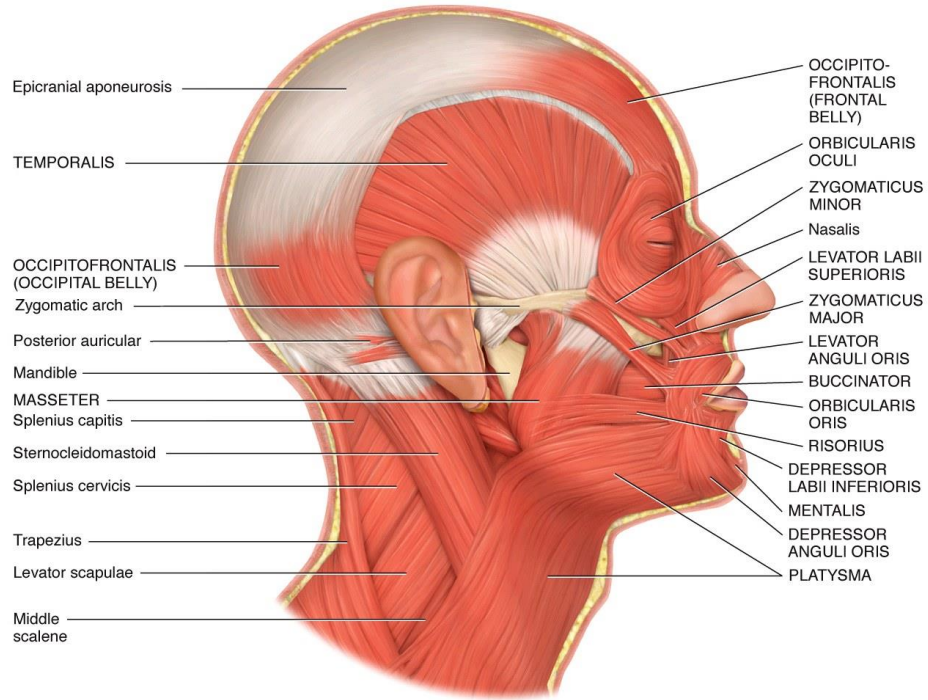

(c) Right lateral superficial view

Nerve and Blood Supply

- Motor Neurons in Nerve
  - Stimulate skeletal muscles to contract
  - Thread-like axon process of neuron extends from brain or spinal cord to a group of muscle fibers
  - Axon end typically branches to extend to different skeletal muscle fibers
- Blood vessels
  - Generally, each muscle has one artery and two veins
  - Plentiful microscopic blood capillaries bring oxygen and nutrients and remove metabolic wastes
  - Each muscle fiber is in close contact with one or more microscopic blood capillaries

Lesson 6: How Does a Muscle Contract?

Objective:

- Describe the components involved in a muscle contraction
- Explain how muscles contract and relax
- Describe the sliding filament model of muscle contraction

Muscle Fiber Structure

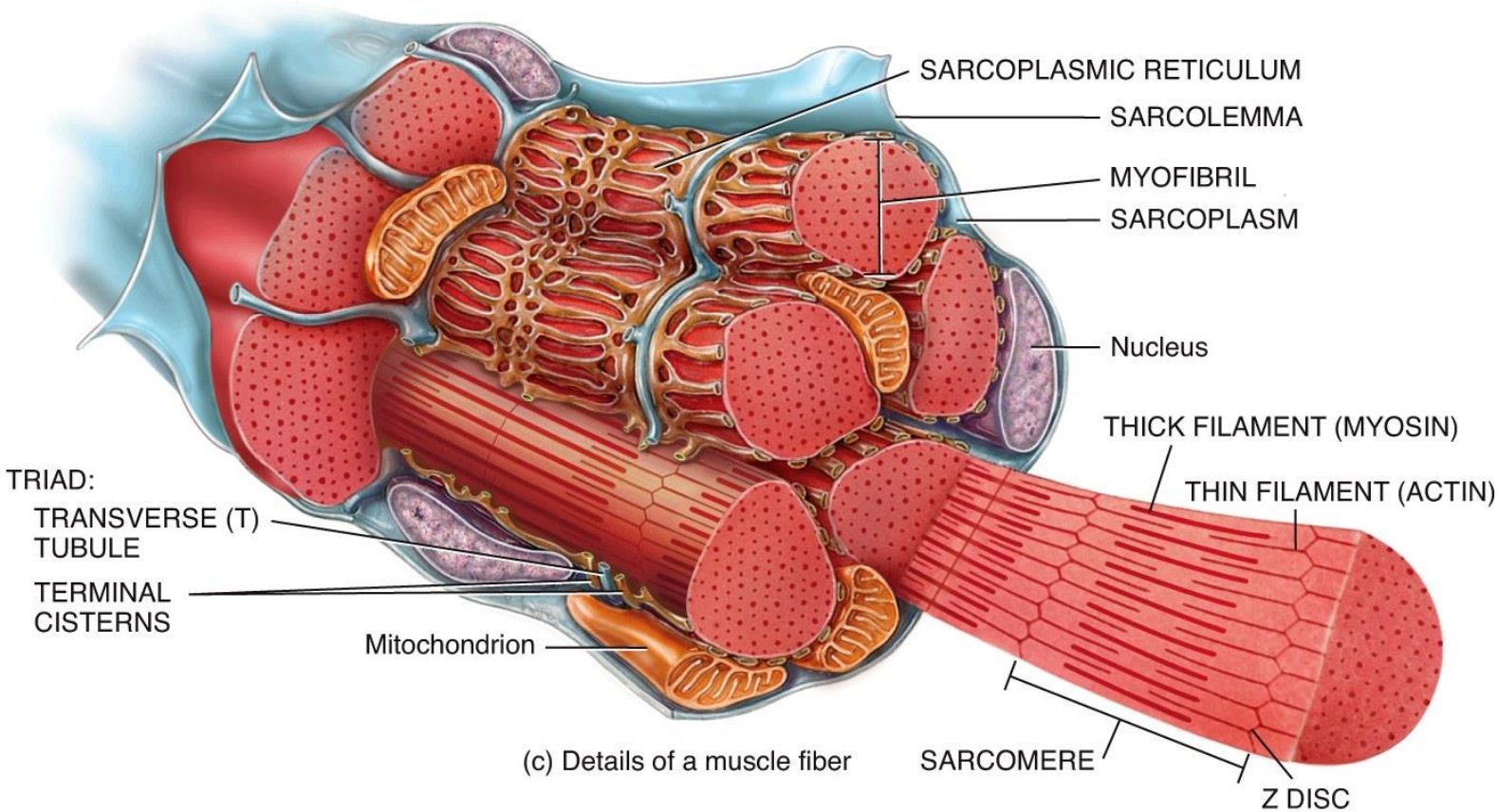

(c) Details of a muscle fiber

Muscle Fiber Structure

- Sarcolemma
  - Plasma membrane of a muscle fiber
  - Muscle action potentials travel along the sarcolemma
- Transverse tubules (T-tubule)
  - Many invaginated, tunnel-like extensions of sarcolemma
  - Open to the cell's exterior, thus filled with interstitial fluid
- Sarcoplasm
  - Cytoplasm of muscle fiber contains organelles
  - Contains glycogen (glucose storage molecule) and myoglobin (oxygen-binding red protein)

- Sarcoplasmic reticulum
  - Fluid-filled, membranous organelle similar to smooth endoplasmic reticulum of non-muscle cells
  - Wraps around each myofibril
  - Dilated end sacs are terminal cisterns, associated with either side of a T-tubule to form a triad
  - Stores and releases calcium ions (Ca^{2+}) that trigger muscle contraction

Muscle Fiber Structure

- Myofibrils
  - Long contractile organelles inside sarcoplasm
  - Extend entire length of muscle fiber
  - Arrangement of filaments gives striated appearance

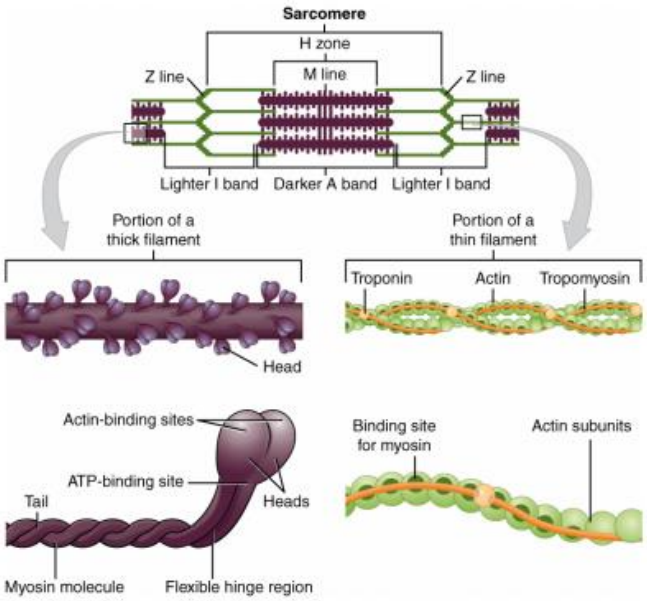

Sarcomere Structure

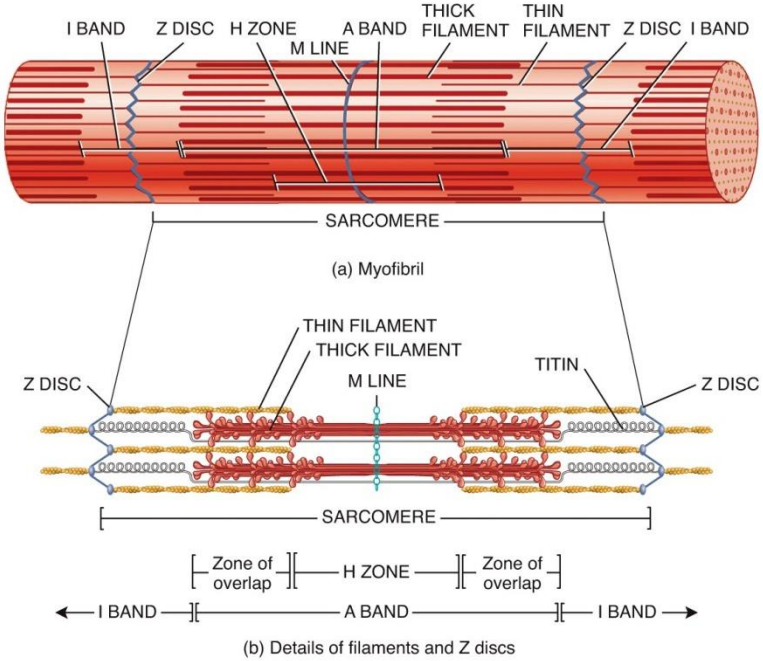

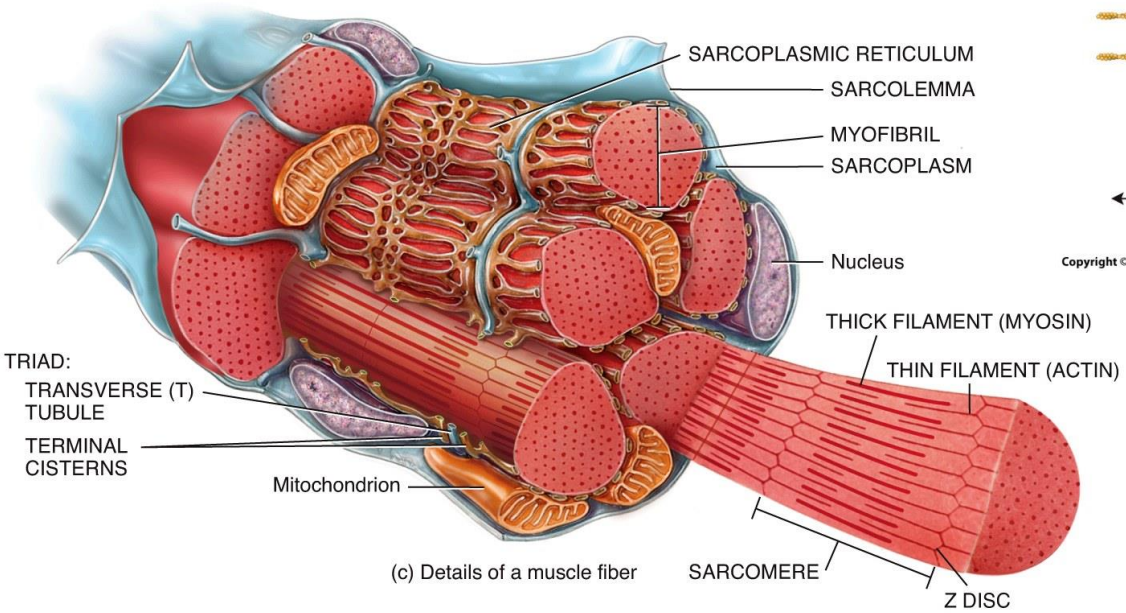

Sarcomere

- Functional unit of contraction within myofibrils
  - Myofibrils extend length of muscle fiber
  - Thick and thin myofilaments in myofibril do not extend entire length of muscle fiber
- Z discs
  - Dense protein material that separates one sarcomere from next in myofibril
- Sarcomeres - alternating bands form striations
  - A band - darker middle with thick and thin overlapping
  - H zone - narrow center with only thick filaments
  - I band - near Z discs with only thin filaments
  - M line - supporting protein in middle of sarcomere

- Muscle Proteins
  - Contractile
    - Myosin - thick myofilament component
      - Molecule shaped like two twisted golf clubs with tail and heads
      - Converts chemical energy in ATP into mechanical energy of motion
    - Actin - thin myofilament component
      - Has myosin-binding site for myosin head
  - Regulatory
    - Tropomyosin - can cover myosin-binding sites on actin
    - Troponin - can bind Ca^{2+} and holds tropomyosin

Muscle Proteins

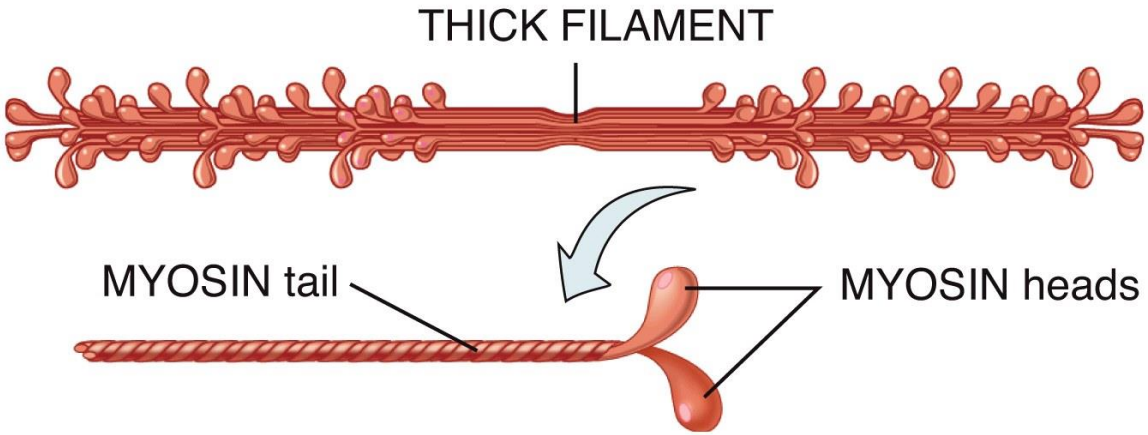

(a) One thick filament (above) and a myosin molecule (below)

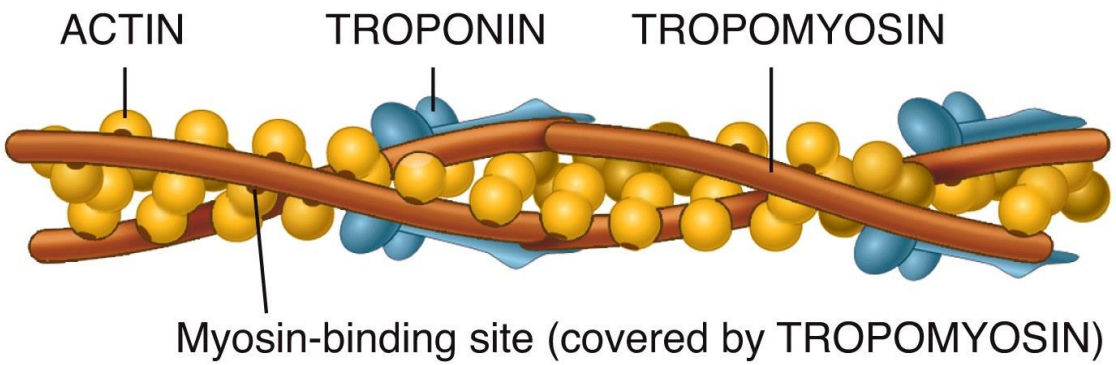

(b) Portion of a thin filament

Muscle Proteins

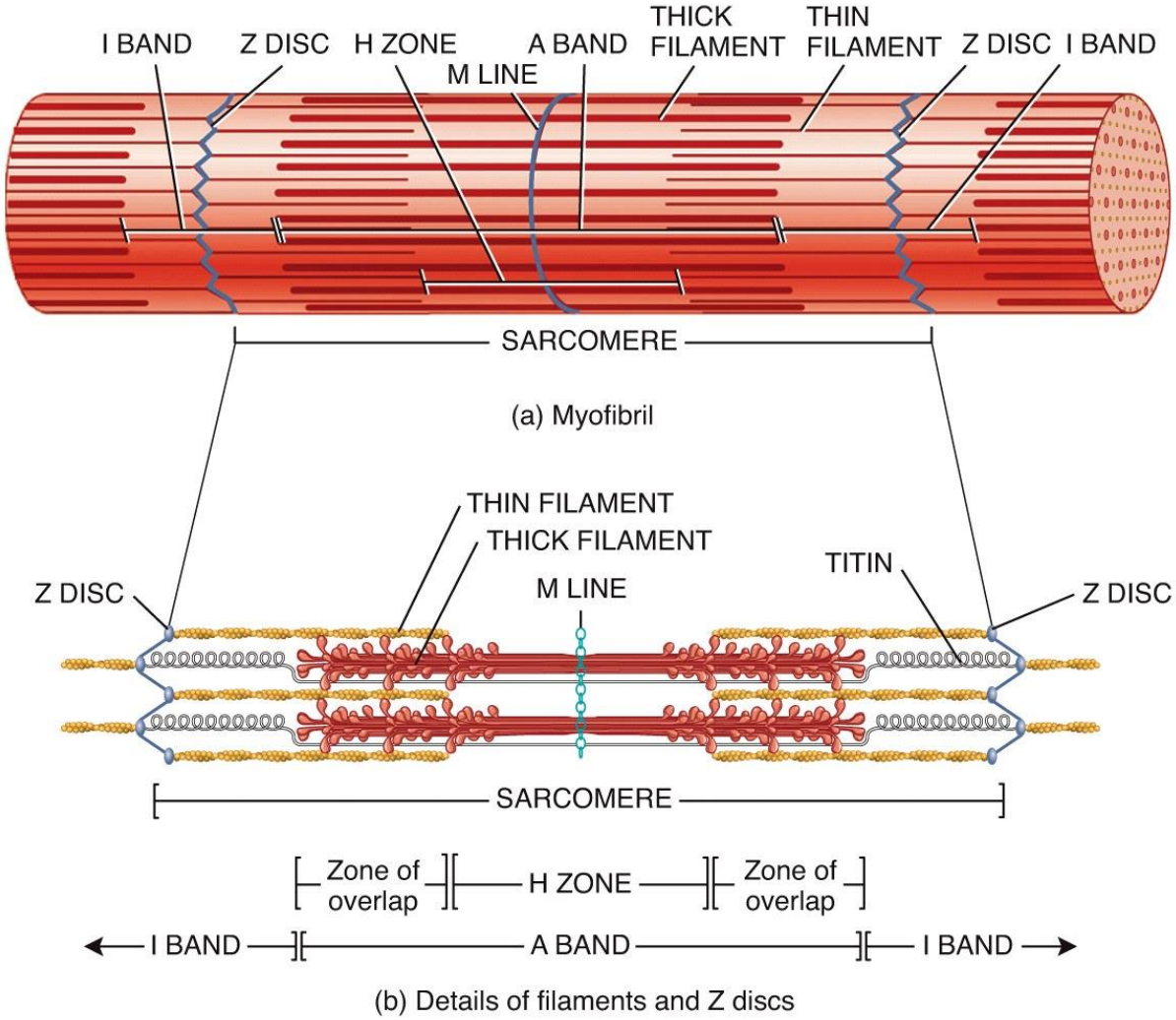

Neuromuscular Junction (NMJ)

- Synapse between a motor neuron and a skeletal muscle fiber
  - Synaptic cleft is gap between the two cells
  - Communication by release of neurotransmitter chemical
- Synaptic end bulb
  - End of motor neuron axon at NMJ
  - Synaptic vesicles contain acetylcholine (Ach)
- Motor end plate
  - Folded region of sarcolemma opposite synaptic end bulb increases surface area
  - Abundant acetylcholine receptors

Neuromuscular Junction (NMJ)

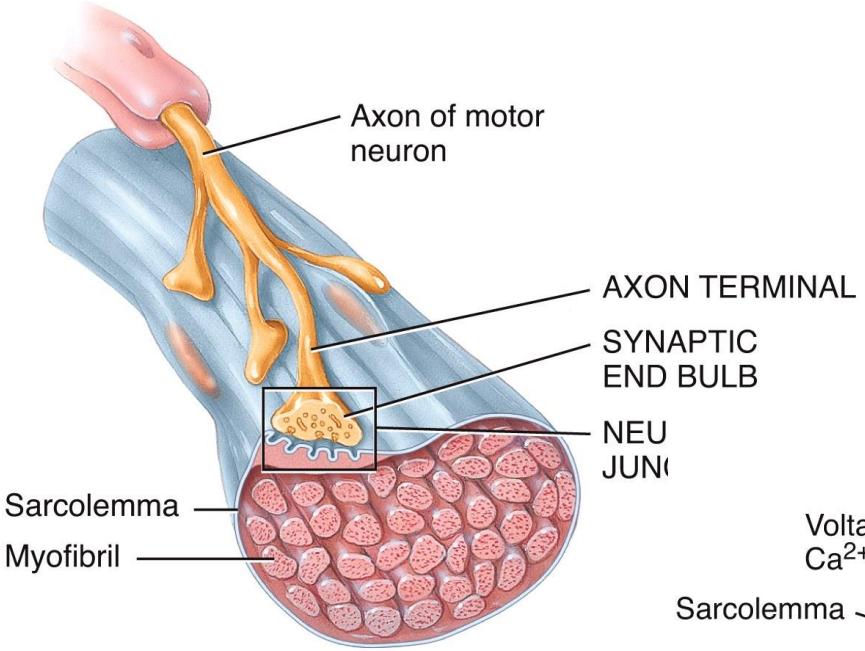

(a) Neuromuscular junction

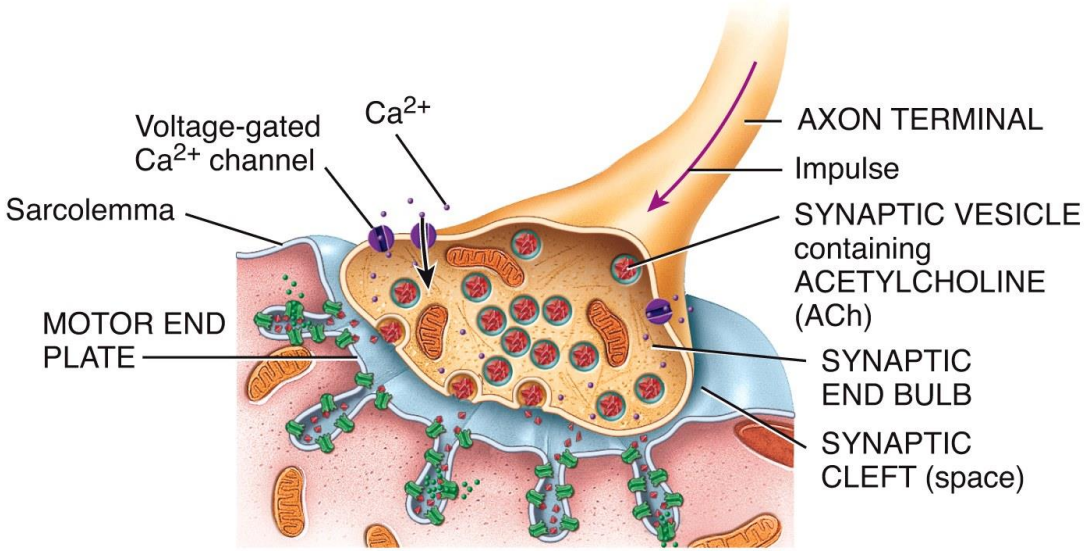

(b) Enlarged view of neuromuscular junction

Neuromuscular Junction (NMJ)

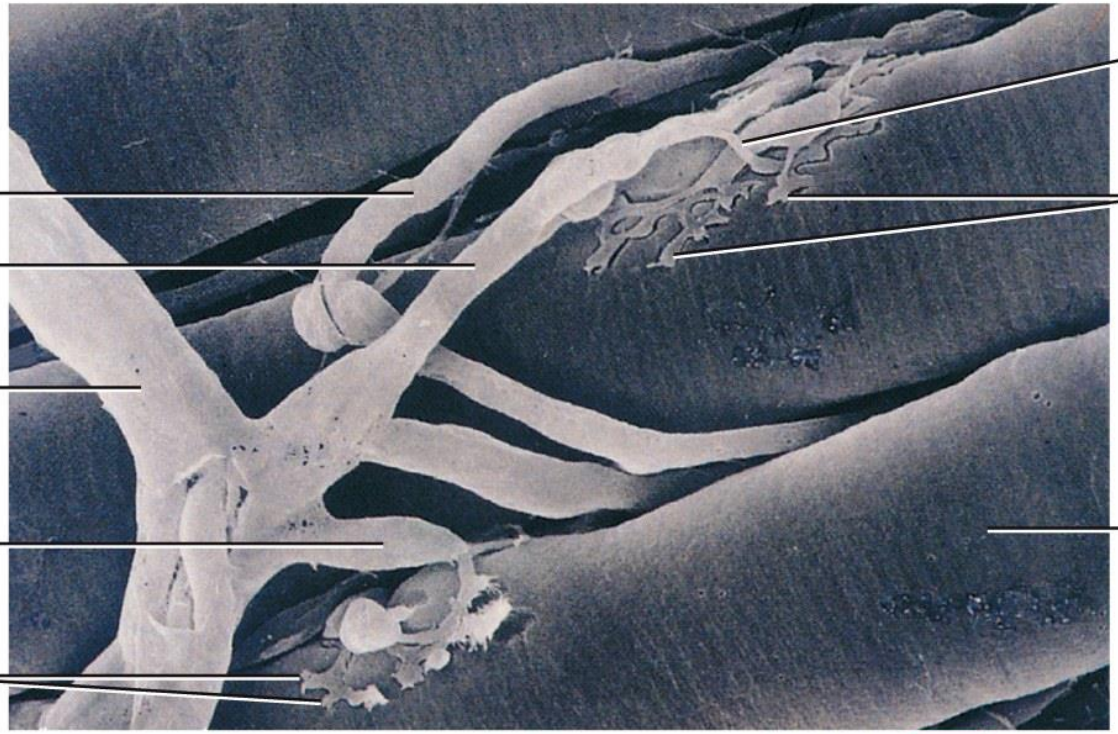

(d) Neuromuscular junction

D.W. Fawcett/Photo Researchers, Inc.

Nerve Impulse Sequence

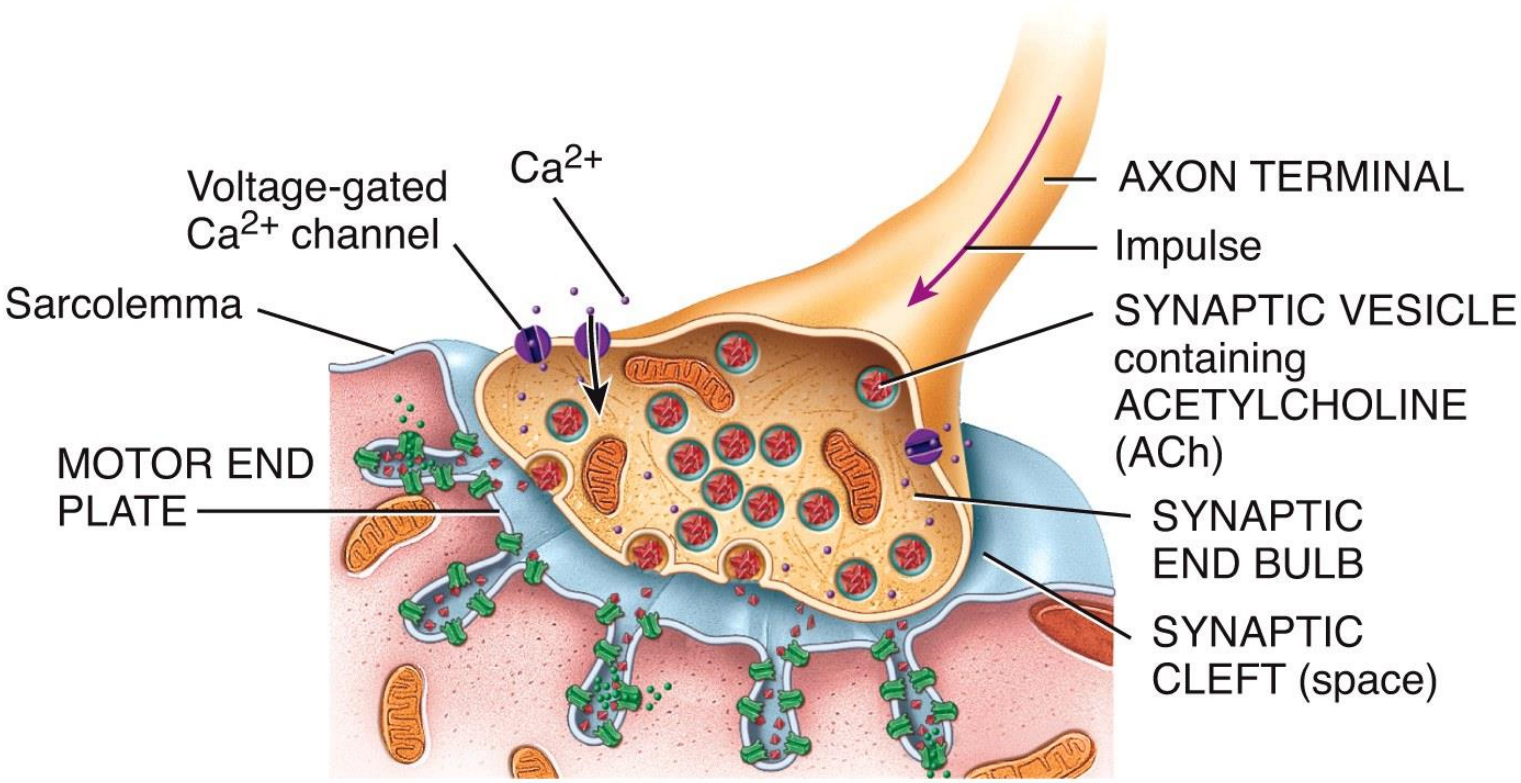

(b) Enlarged view of
neuromuscular junction

Muscle contraction

- **Muscle activation:** The motor nerve stimulates an action potential (impulse) to pass down a neuron to the neuromuscular junction. This stimulates the sarcoplasmic reticulum to release calcium into the muscle cell.
- **Muscle contraction:** Calcium floods into the muscle cell binding with troponin allowing actin and myosin to bind. The actin and myosin cross bridges bind and contract using ATP as energy.
- **Recharging:** ATP is re-synthesized allowing actin and myosin to maintain their strong binding state

- **Relaxation:**
  - stimulation of the nerve stops.
  - Calcium pumped back into the sarcoplasmic reticulum breaking the link between actin and myosin.
  - Actin and myosin return to their unbound state causing the muscle to relax.
  - Alternatively, relaxation (failure) will also occur when ATP is no longer available.

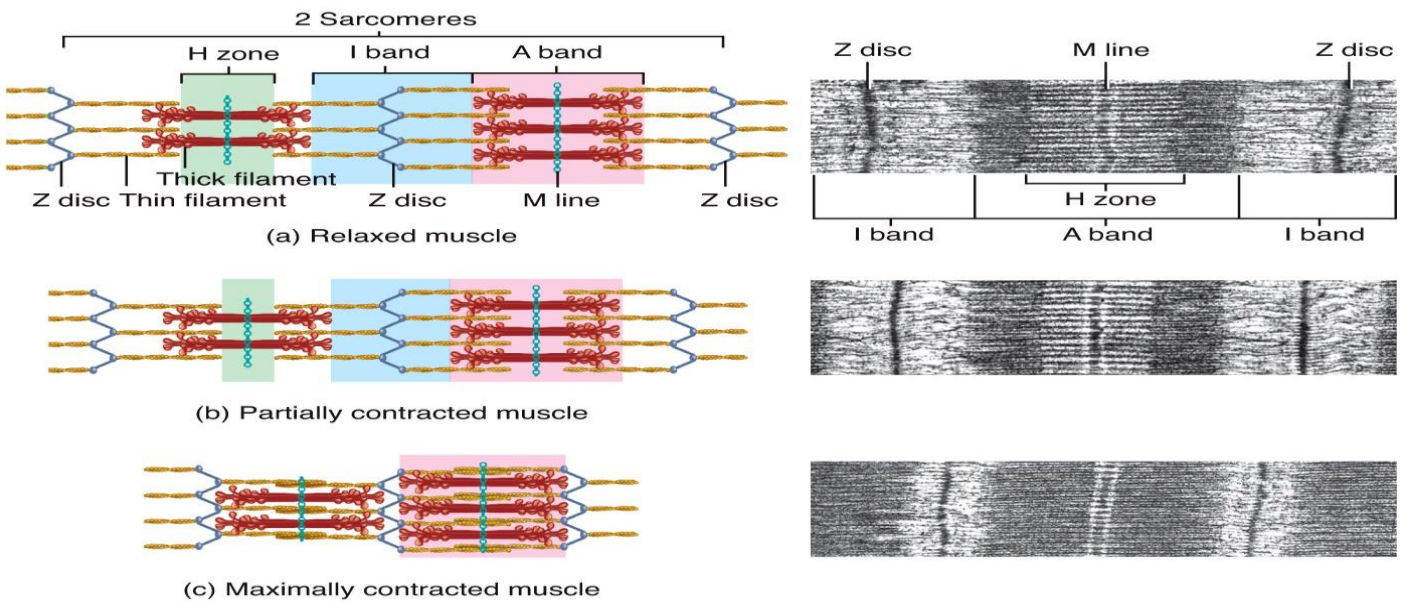

Contraction and Relaxation Summary

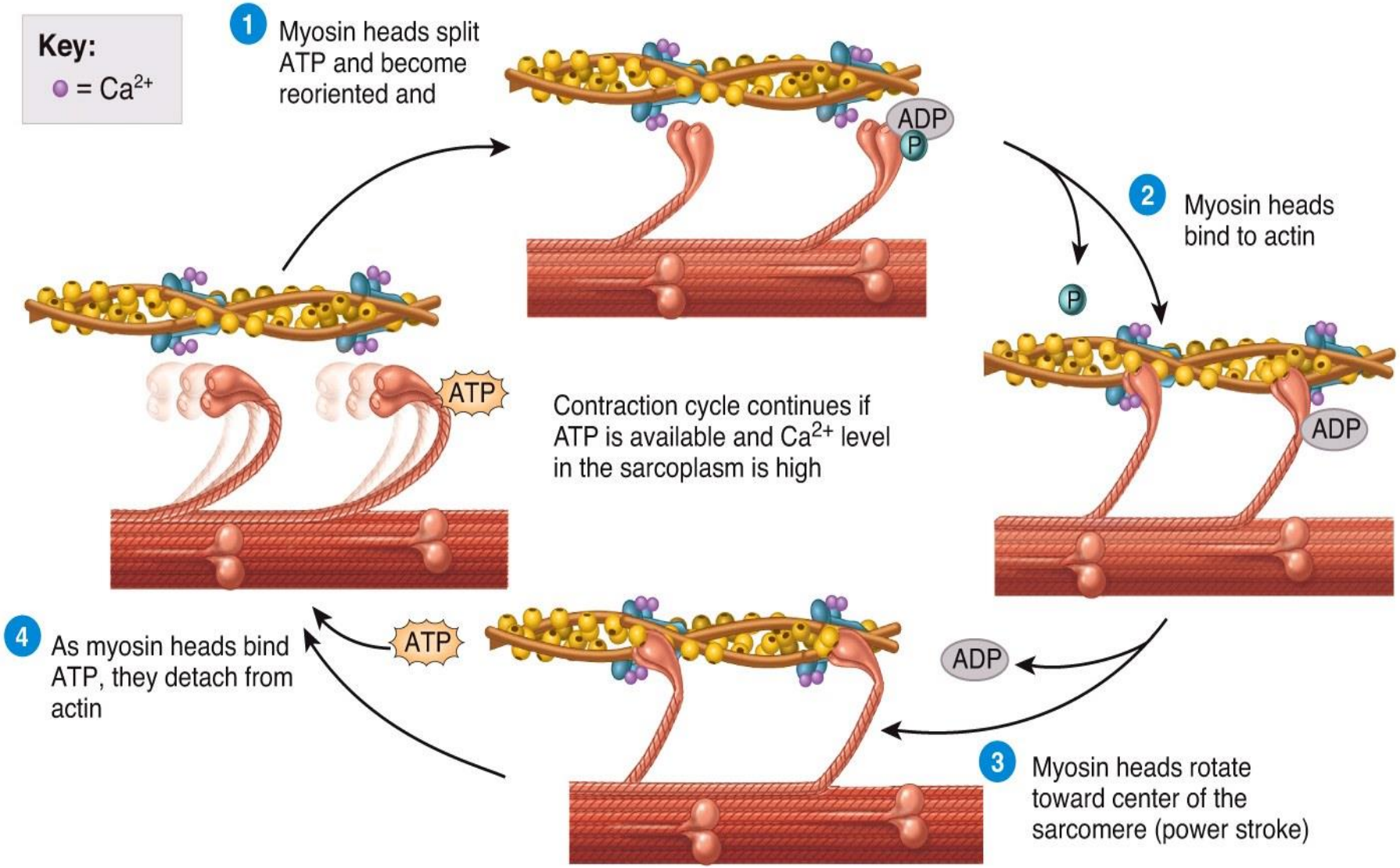

Lesson 7: Interactions of Skeletal Muscles and body movement

Objective:

- Compare and contrast agonist and antagonist muscles
- Explain the major events of a skeletal muscle contraction within a muscle in generating force
- Differentiate among the types of movements possible at synovial joints

Muscular system

- The is made up of voluntarily controlled skeletal muscles in the body
  - There are almost 700 individual skeletal muscles
- Primary function is to produce movement of a body part
  - Contraction of skeletal muscle pulls on bones to cause movement
  - Muscle can only pull on bones, they cannot push
  - A few skeletal muscles stabilize bones during movement by other skeletal muscles

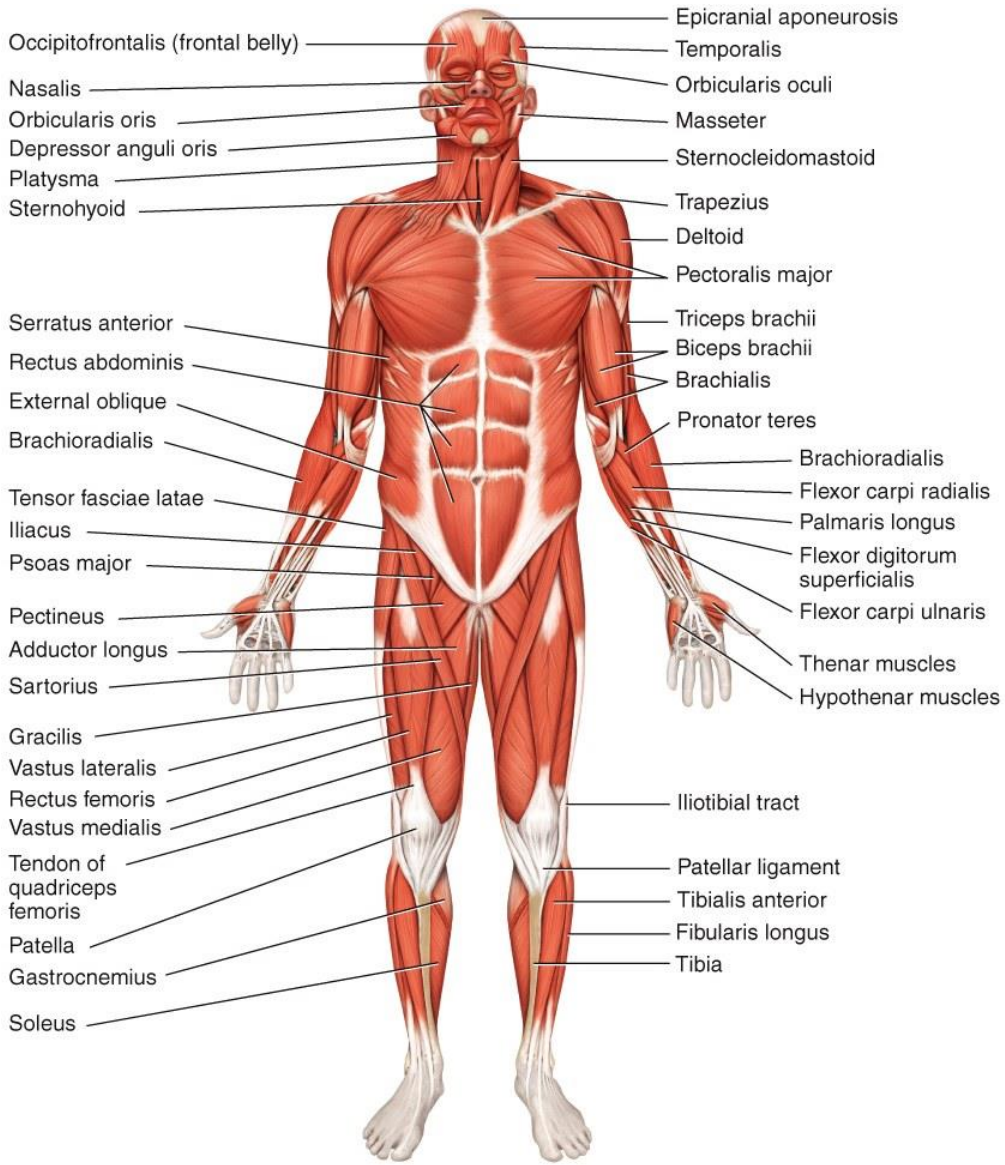

(a) Anterior view

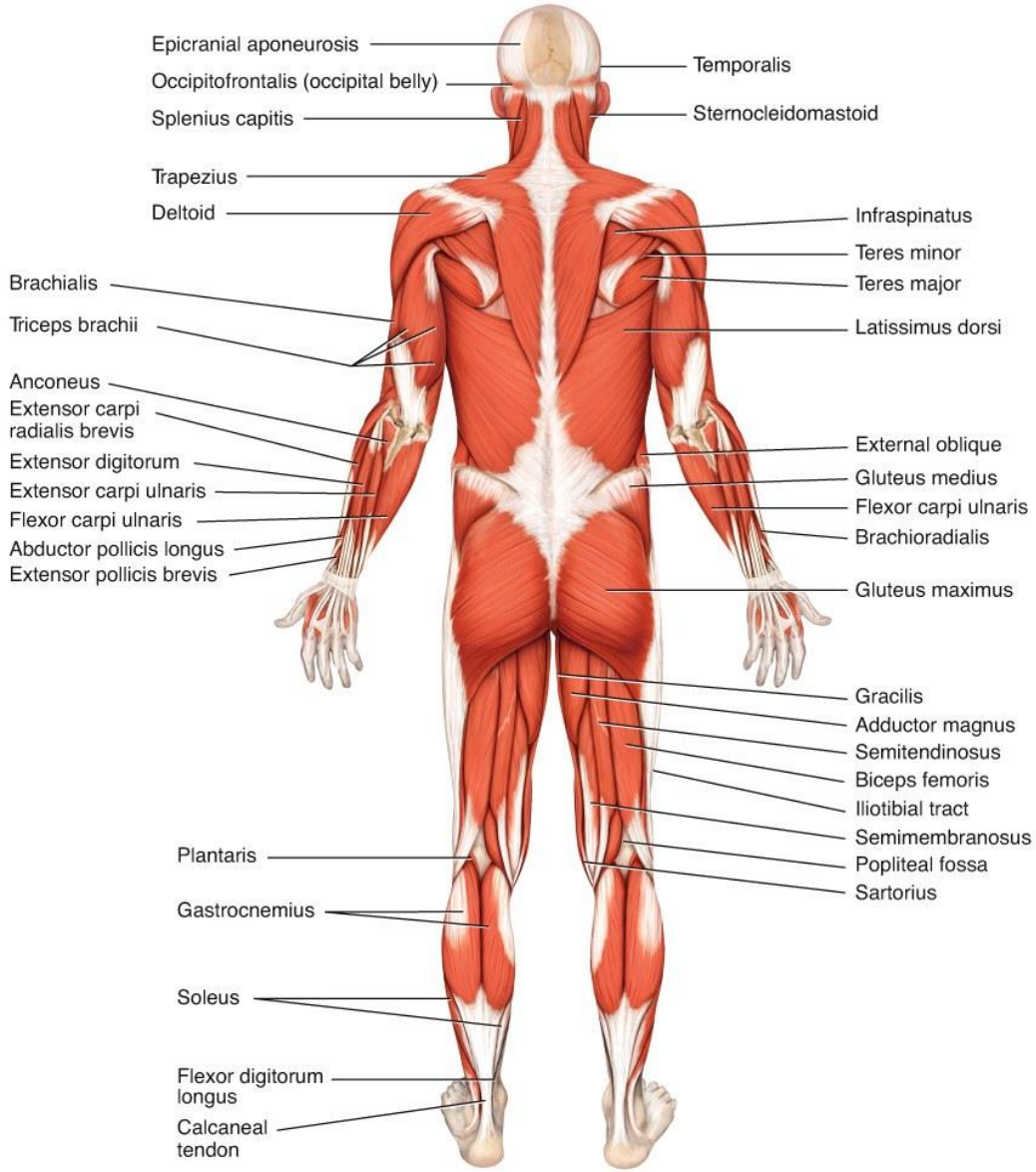

(b) Posterior view

Muscle Attachment Sites

- Most muscles are attached via two tendons to bones
- Two articulating bones usually don't move equally in response to contraction of muscle
  - Origin - the attachment that is usually stationary
  - Insertion - the attachment at a site that usually moves as a muscle contracts
  - Some bones have multiple origins or insertions
  - Some muscles cross two joints and have more complex actions

Muscle Attachment Sites

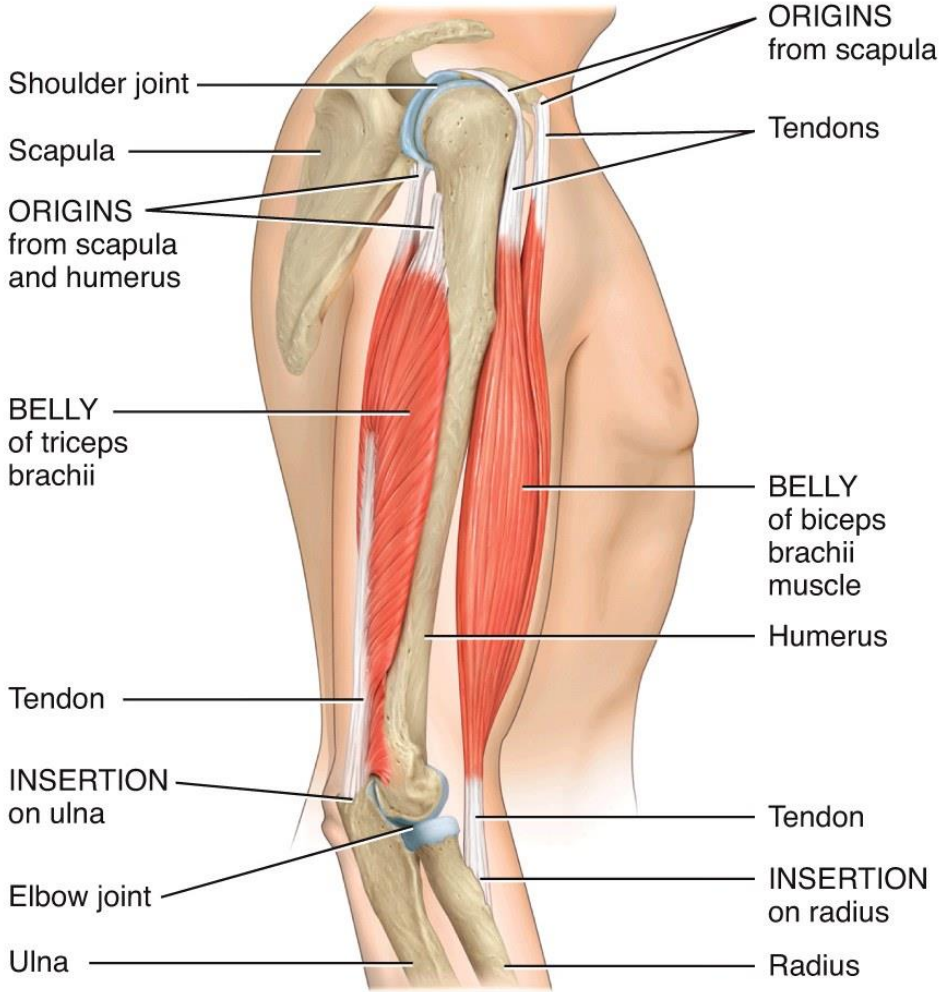

(a) Origin and insertion of a skeletal muscle

Lever Systems and Leverage

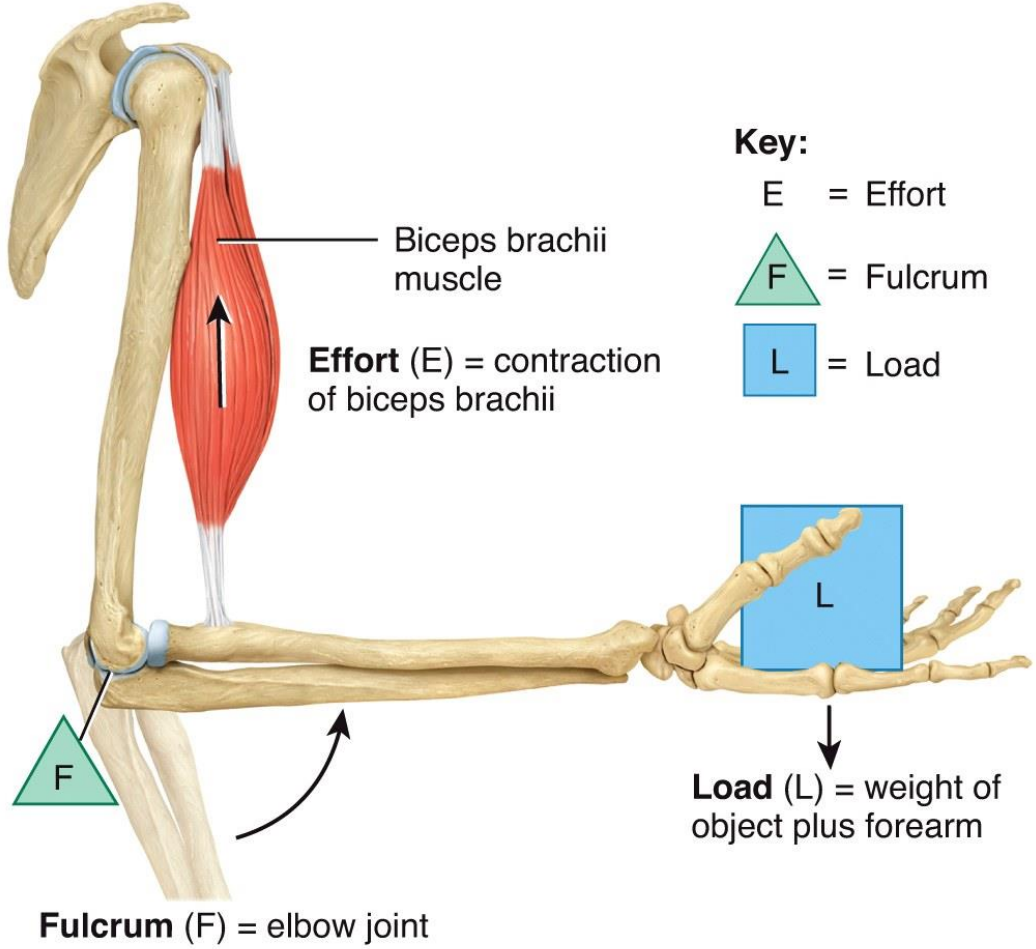

(b) Movement of forearm lifting a weight

Lever Systems and Leverage

- A lever is a rigid structure that moves around a fixed point called a fulcrum
  - Bones act as levers
  - Joints act as fulcrums
- Two forces act on a lever
  - Effort - causes movement
    - Skeletal muscles exert force of effort
  - Load - resists movement
    - Weight of body part is typically the load
- Motion occurs when the effort applied to bone at insertion is greater than the load

Types of Contractions

- Isotonic contraction
  - Involves a change in muscle length without a change in its tension
  - Concentric - when muscle shortens
  - Eccentric - when muscle lengthens
- Isometric contraction
  - Muscle does not change length
  - The load equals or exceeds the muscle tension created

Types of Contractions



(a) Concentric contraction while picking up a book



(b) Eccentric contraction while lowering a book



(c) Isometric contraction while holding a book steady

Antagonistic muscle action

Muscles are arranged in **antagonistic pairs**. As one muscle contracts (shortens) the other relaxes (lengthens).

Antagonistic muscle action

Agonist – the contracting muscle responsible for causing movement.

Antagonist – relaxing + lengthening muscle which allows the movement. *(The muscle that works in opposition to the agonist)*

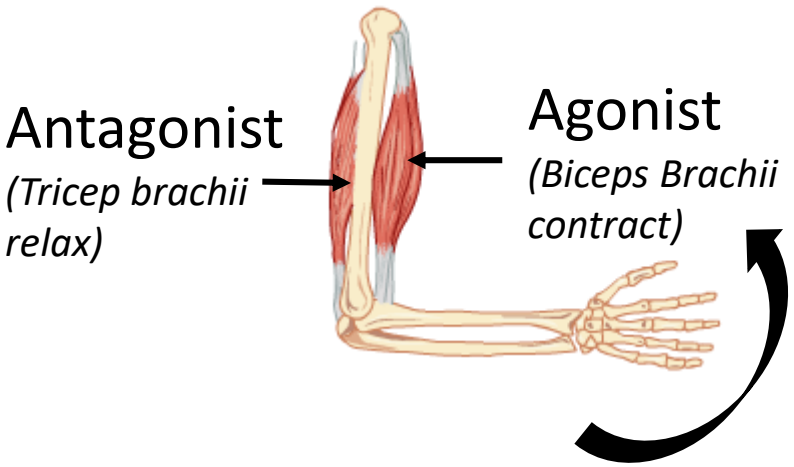

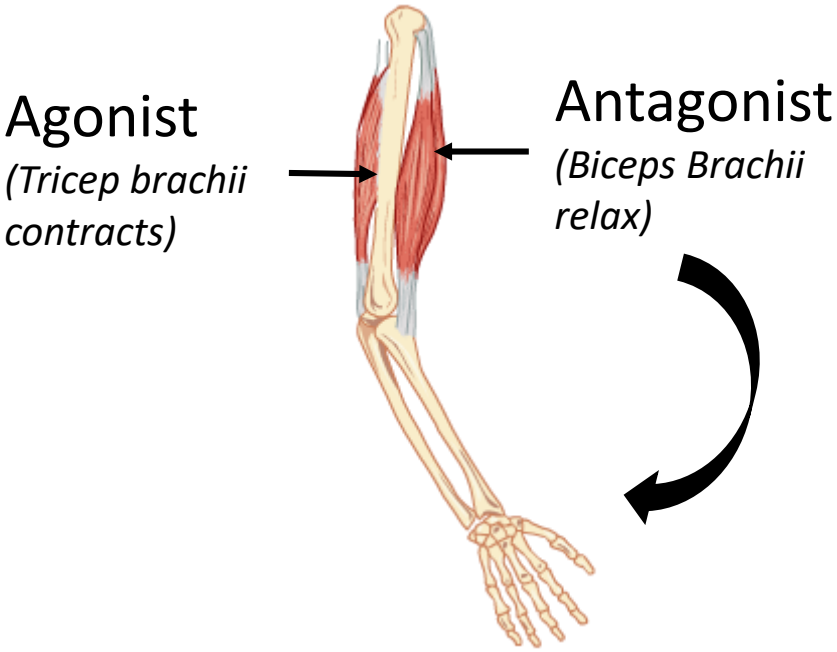

Fixator – a muscle that stabilises one part of a body while the other moves.

Antagonistic muscle action

Plantar Flexion - Gastrocnemius and Soleus (Agonist) and Tibialis Anterior (Antagonist)

Flexion at the knee - Biceps Femoris (Agonist) and Rectus Femoris (Antagonist)
Fixator - Gluteus Maximus

Types of Ordinary Body Movements

- **Flexion**
  - Decreases the angle of the joint
  - Brings two bones closer together
  - Typical of hinge joints like knee and elbow
- **Extension**
  - Opposite of flexion
  - Increases angle between two bones

Types of Ordinary Body Movements

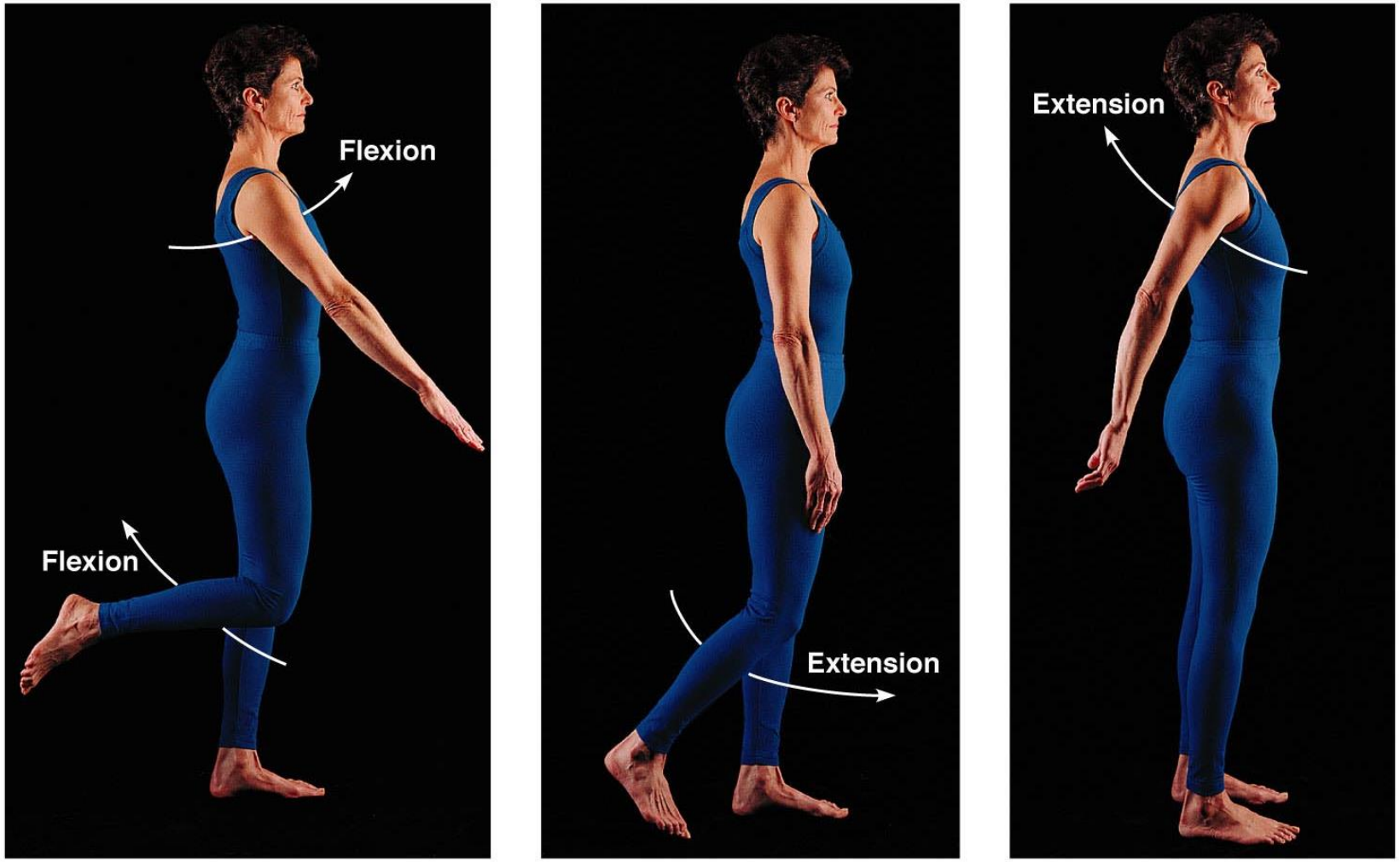

(a) Flexion and extension of the shoulder and knee

Types of Ordinary Body Movements

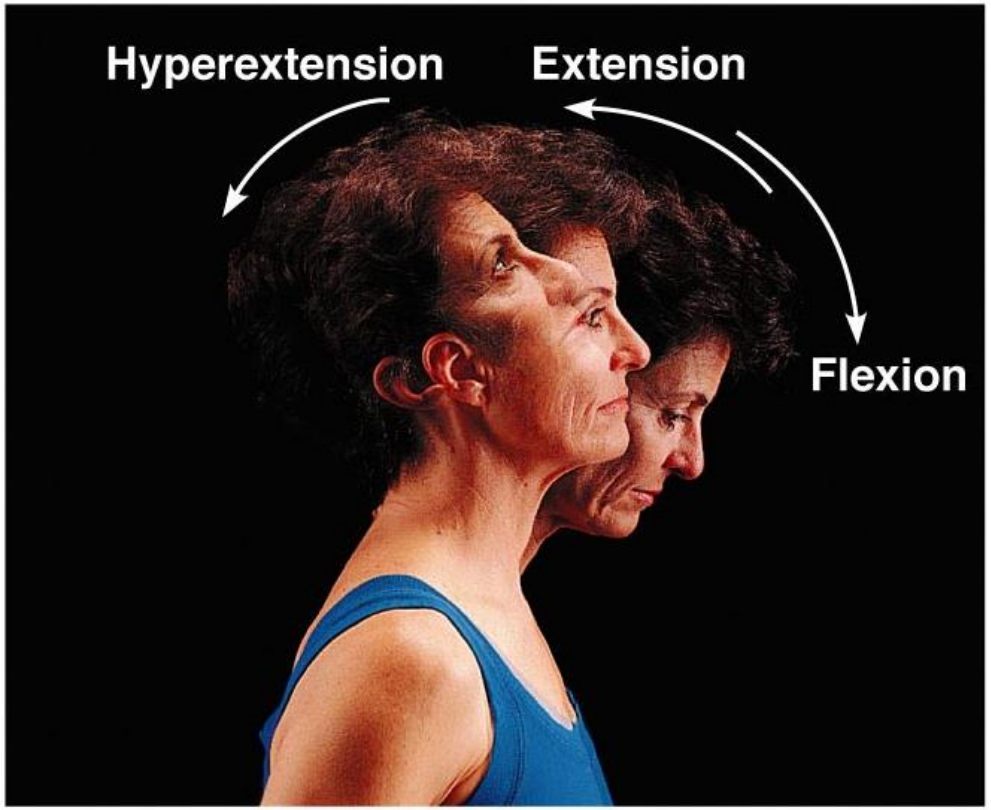

(b) Flexion, extension, and hyperextension

Hyperextension: results when angle is > 180˚

Types of Ordinary Body Movements

- **Rotation**
  - Movement of a bone around its longitudinal axis
  - Common in ball-and-socket joints
  - Example is when you move atlas around the axis vertebra (shake your head “no”)

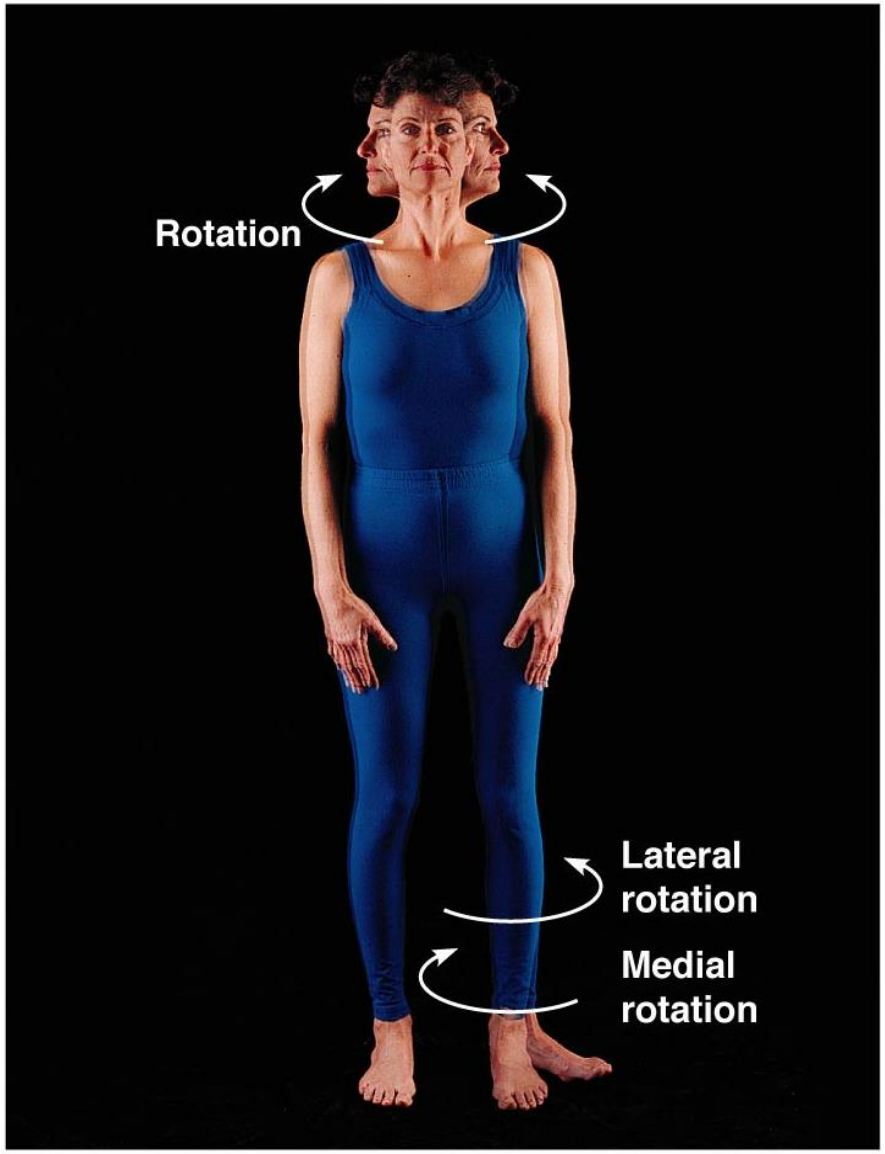

(c) Rotation

Types of Ordinary Body Movements

- **Abduction**
  - Movement of a limb awa
    from the midline
- **Adduction**
  - Opposite of abduction
  - Movement of a limb
    toward the midline

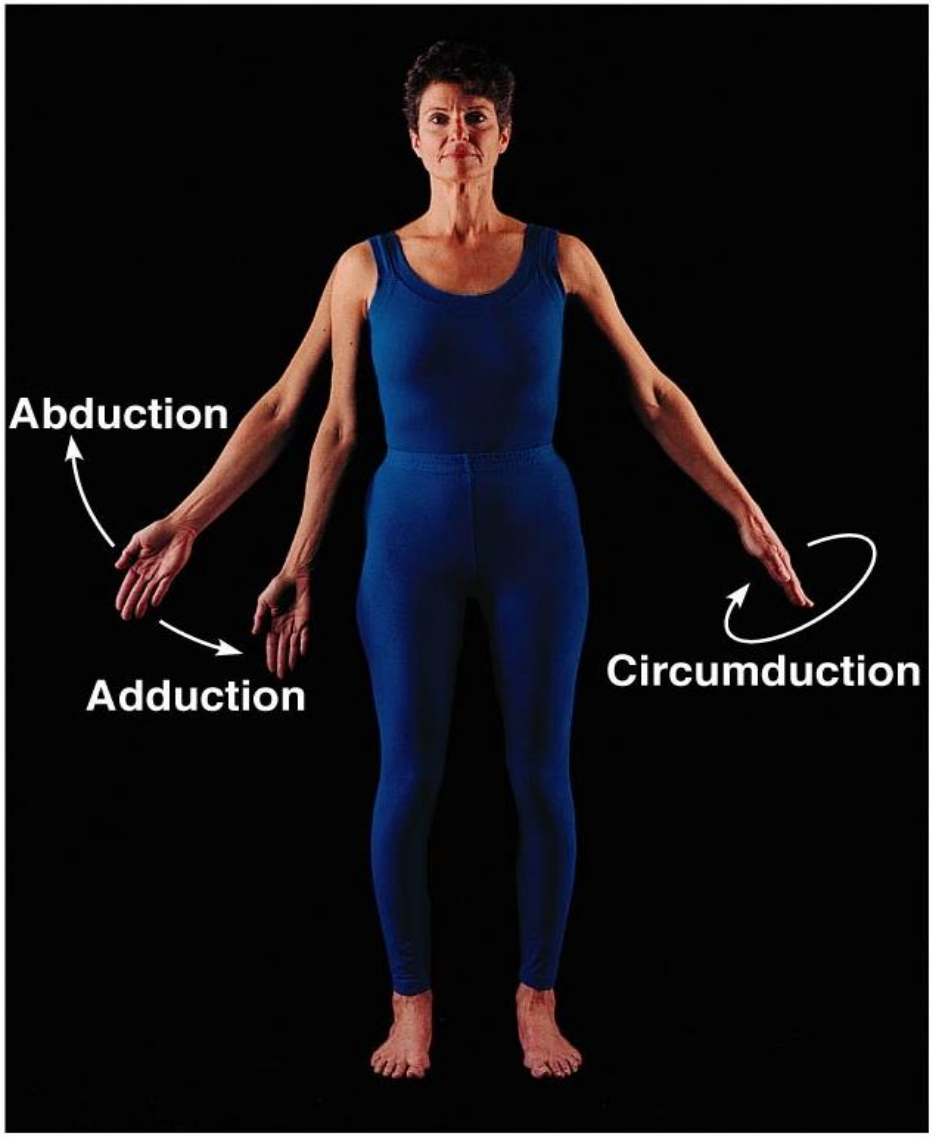

(d) Abduction, adduction, and circumduction

Types of Ordinary Body Movements

- **Circumduction**
  - Combination of flexion, extension, abduction, and adduction
  - Common in ball-and-socket joints

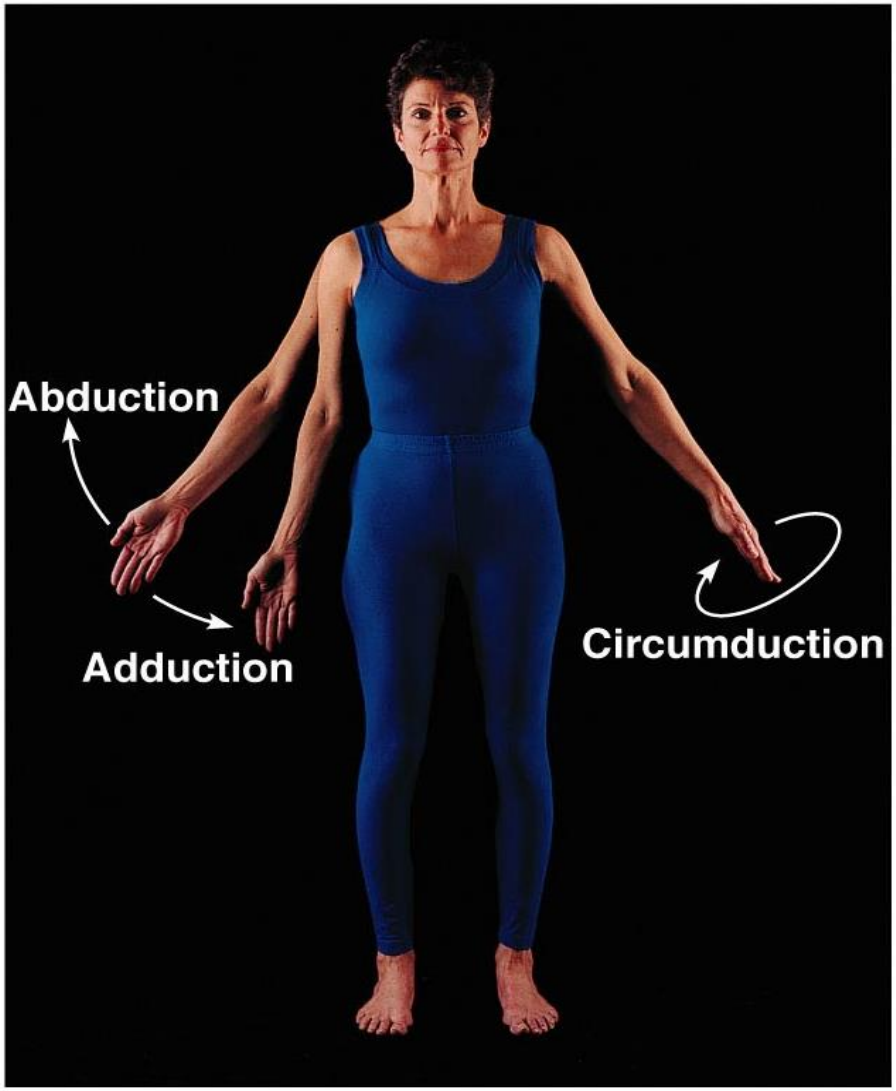

(d) Abduction, adduction, and circumduction

Special Movements

- **Dorsiflexion**
  - Lifting the foot so that the superior surface approaches the shin
- **Plantar flexion**
  - Depressing the foot (pointing the toes)

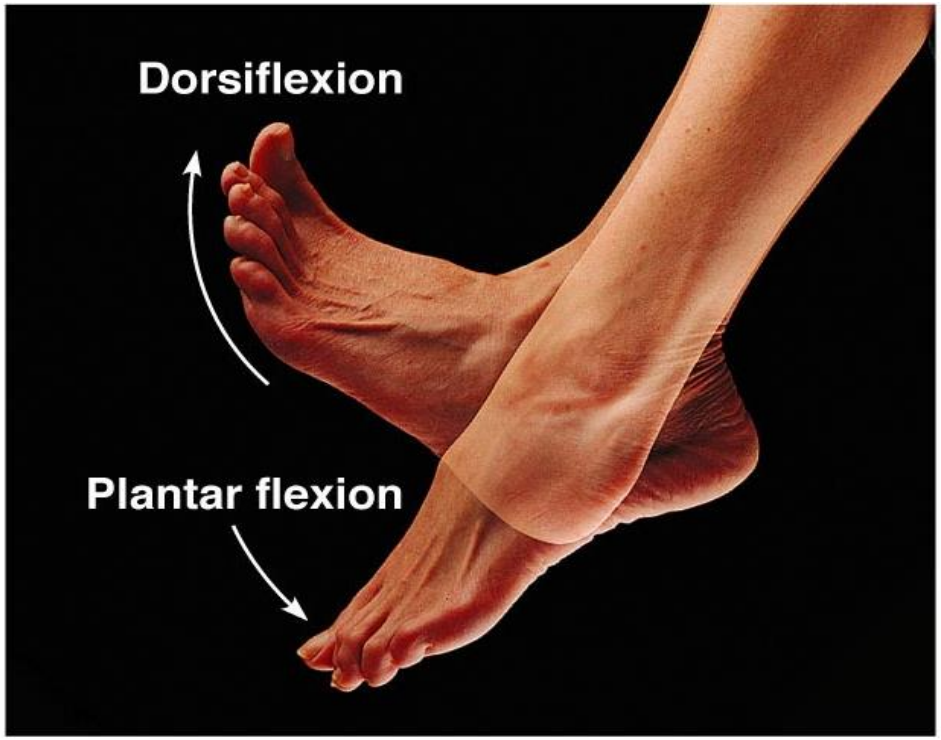

(e) Dorsiflexion and plantar flexion

Special Movements

- **Inversion**
  - Turn sole of foot medially
- **Eversion**
  - Turn sole of foot laterally

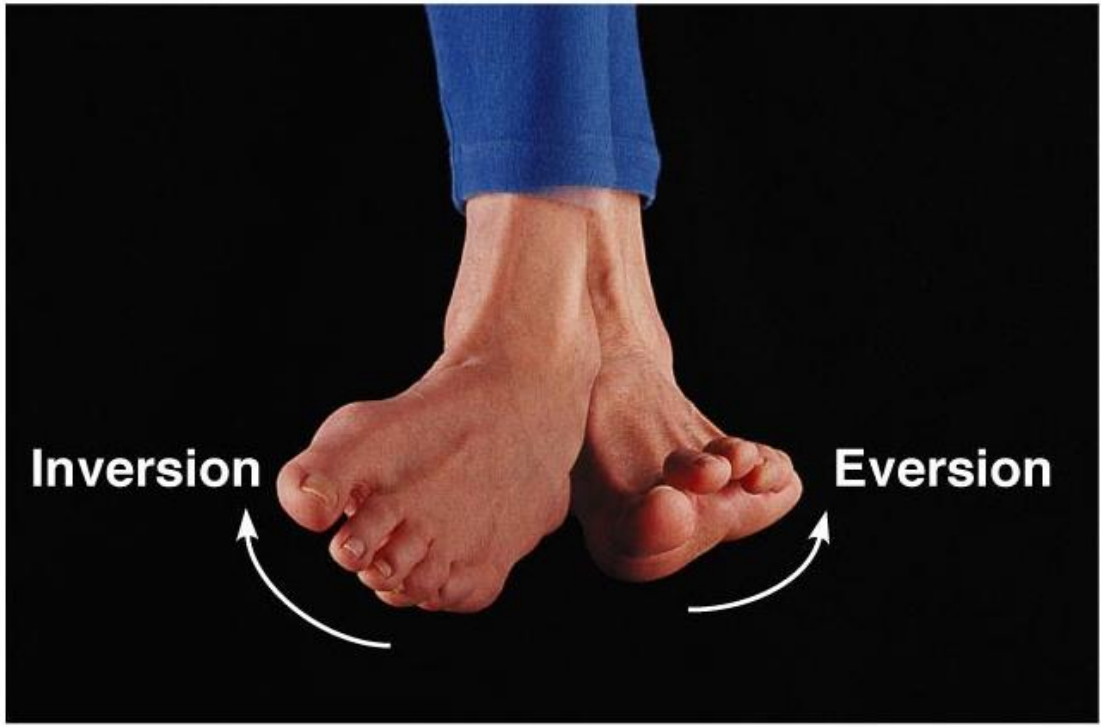

(f) Inversion and eversion

Special Movements

- **Supination**
  - Forearm rotates laterally so palm faces up (anterior)
- **Pronation**
  - Forearm rotates medially so palm faces down (posterior)

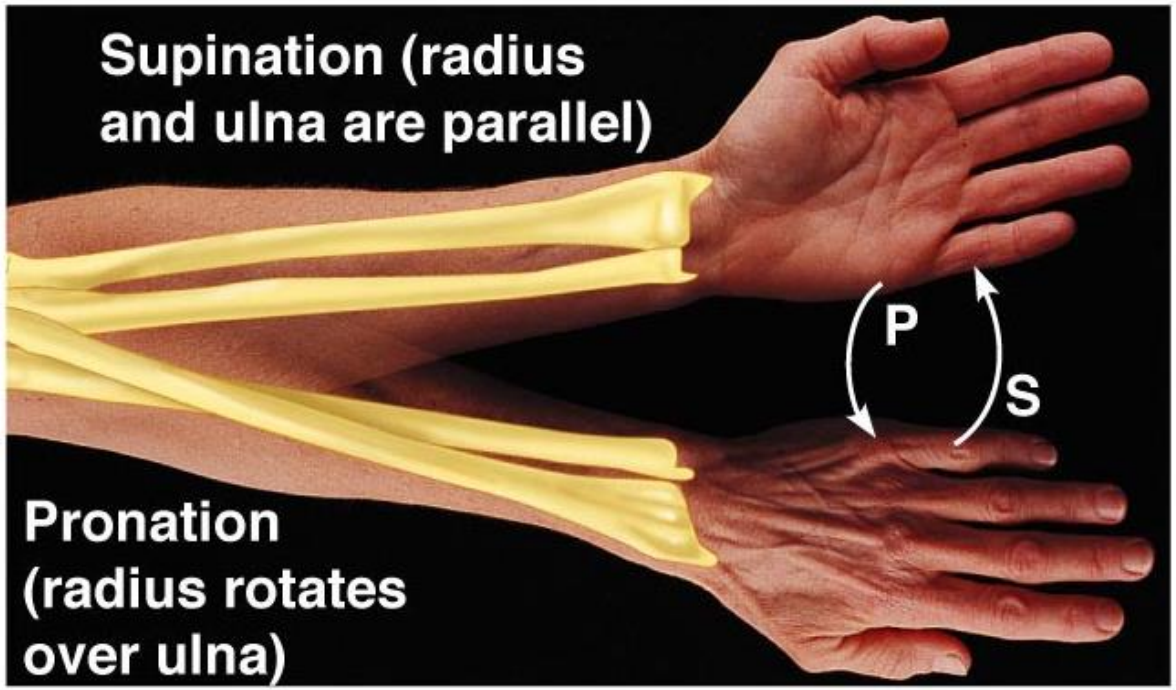

(g) Supination (S) and pronation (P)

Special Movements

- **Opposition**
  - Move thumb to touch the tips of other fingers on the same hand

(h) Opposition