Unit 4: Tissues

Ms. Randall

Essential Questions:

- How are structure and function related for each of the types of body tissues?

Unit Objectives:

- Classify and state the defining characteristics of epithelial, connective tissue, muscle tissue, and nervous tissue.
- Describe the general characteristics and functions of epithelial tissue.
- Explain how glands are classified.
- Describe the four major types of membranes.
- Determine the relationship between form and function for each type of epithelial tissue.
- Analyze how connective tissue establishes the framework of the body.
- Analyze the three muscle tissue types and the special structure features of each type.
- Analyze the basic structure and role of neural tissue.
- Determine how tissue injury is repaired

Unit Vocabulary:

Cell junctions
Tissue
Epithelium
Striated
Avascular
Vascular
Squamous
Keratinized
Exocrine
Endocrine
Apoptosis
Vasodilation
Neuron
Action potential
Neuroglia
Angiogenesis
Action potential
Synapse
Areolar tissue
Adipose
Basement membrane
Dense connective
Simple squamous
Loose connective
Simple cuboidal
Hyaline cartilage
Simple columnar
Elastic cartilage
Pseudostratified columnar
Fibrocartilage
Stratified squamous
Stratified cuboidal
Bone
Transitional epithelium
Osteocytes
Glandular epithelium
Connective tissue
Skeletal muscle
Collagen
Smooth muscle
Reticulin
Cardiac muscle

Lesson 1: What are tissues?

Objective:

- Distinguish among the structure and function of the four basic types of body tissues.
- Describe the structure and functions of cell junctions.

Histology ('histo' meaning 'tissue' or 'web' in Greek) is the study of normal cells and tissues, mainly with the use of a microscope. It involves all aspects of tissue biology, focusing on how cells' structure and arrangement optimize functions specific for each organ.

The sound knowledge of these normal histologic structures is essential for understanding the histopathology or pathology of any disease, which often cause specific changes in cells and tissues.

Cell Diversity

Cells are specialized for particular functions. Each cell has specific structures and functions based on its location in the body.

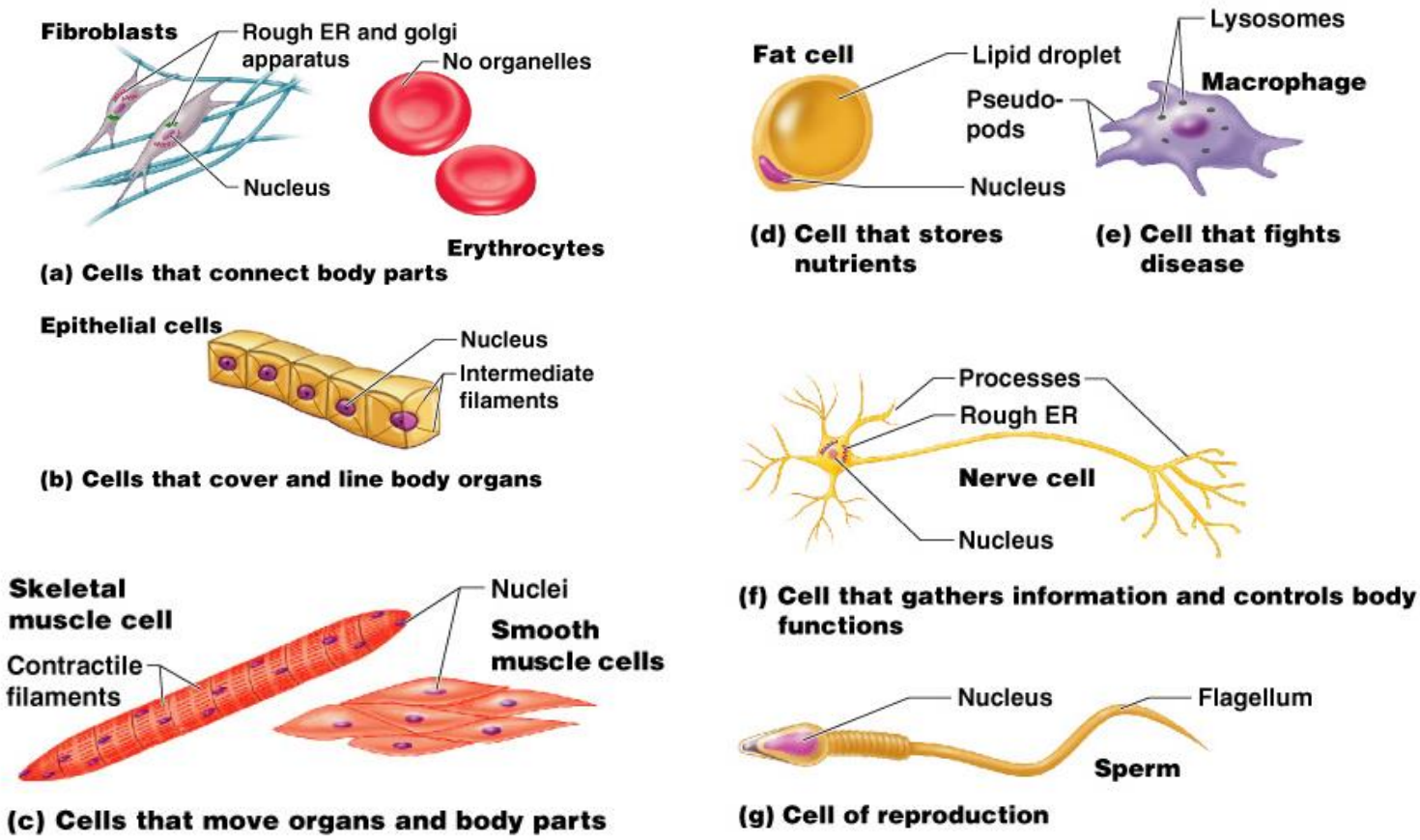

Watch This: Types of Tissues

The term **tissue** is used to describe a group of cells found together in the body. The cells within a tissue share a common embryonic origin. Microscopic observation reveals that the cells in a tissue share morphological features and are arranged in an orderly pattern that achieves the tissue's functions. From the evolutionary perspective, tissues appear in more complex organisms. For example, multicellular protists, ancient eukaryotes, do not have cells organized into tissues.

Although there are many types of cells in the human body, they are organized into four broad categories of tissues: epithelial, connective, muscle, and nervous. Each of these categories is characterized by specific functions that contribute to the overall health and maintenance of the body. A disruption of the structure is a sign of injury or disease. Such changes can be detected through **histology**, the microscopic study of tissue appearance, organization, and function.

Tissue Membranes

A **tissue membrane** is a thin layer or sheet of cells that covers the outside of the body (for example, skin), the organs (for example, pericardium), internal passageways that lead to the exterior of the body (for example, abdominal mesenteries), and the lining of the moveable joint cavities. There are two basic types of tissue membranes: connective tissue and epithelial membranes. The two broad categories of tissue membranes in the body are (1) connective tissue membranes, which include synovial membranes, and (2) epithelial membranes, which include mucous membranes, serous membranes, and the cutaneous membrane, in other words, the skin.

Connective Tissue Membranes

The **connective tissue membrane** is formed solely from connective tissue. These membranes encapsulate organs, such as the kidneys, and line our movable joints. A **synovial membrane** is a type of connective tissue membrane that lines the cavity of a freely movable joint. For example, synovial membranes surround the joints of the shoulder, elbow, and knee. Fibroblasts in the inner layer of the synovial membrane release hyaluronan into the joint cavity. The hyaluronan effectively traps available water to form the synovial fluid, a natural lubricant that enables the bones of a joint to move freely against one another without much friction. This synovial fluid readily exchanges water and nutrients with blood, as do all body fluids.

The **meninges** are a connective tissue covering on the brain and spinal cord, within the dorsal cavity, are called meninges. They provide protection for these vital structures.

Epithelial Membranes

The **epithelial membrane** is composed of epithelium attached to a layer of connective tissue, for example, your skin. The **mucous membrane** is also a composite of connective and epithelial tissues. Sometimes called mucosae, these epithelial membranes line the body cavities and hollow passageways that open to the external environment, and include the digestive, respiratory, excretory, and reproductive tracts. Mucous, produced by the epithelial exocrine glands, covers the epithelial layer. The underlying connective tissue, called the **lamina propria** (literally "own layer"), help support the fragile epithelial layer. A **serous membrane** is an epithelial membrane composed of mesodermally derived epithelium called the mesothelium that is supported by connective tissue. These membranes line the coelomic cavities of the body, that is, those cavities that do

not open to the outside, and they cover the organs located within those cavities. They are essentially membranous bags, with mesothelium lining the inside and connective tissue on the outside. Serous fluid secreted by the cells of the thin squamous mesothelium lubricates the membrane and reduces abrasion and friction between organs. Serous membranes are identified according locations. Three serous membranes line the thoracic cavity; the two pleura that cover the lungs and the pericardium that covers the heart. A fourth, the peritoneum, is the serous membrane in the abdominal cavity that covers abdominal organs and forms double sheets of mesenteries that suspend many of the digestive organs.

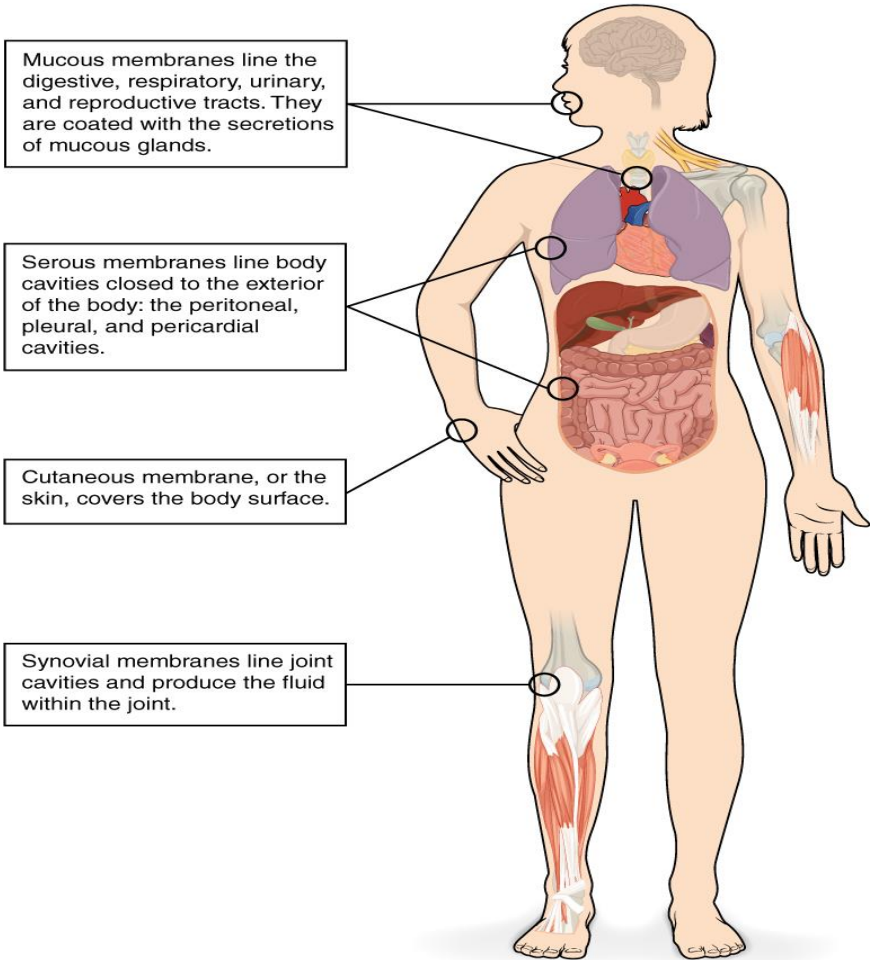

The skin is an epithelial membrane also called the **cutaneous membrane**. It is a stratified squamous epithelial membrane resting on top of connective tissue. The apical surface of this membrane is exposed to the external environment and is covered with dead, keratinized cells that help protect the body from desiccation and pathogens.

The Four Types of Tissues

Epithelial tissue, also referred to as epithelium, refers to the sheets of cells that cover exterior surfaces of the body, lines internal cavities and passageways, and forms certain glands. **Connective tissue**, as its name implies, binds the cells and organs of the body together and functions in the protection, support, and integration of all parts of the body. **Muscle tissue** is excitable, responding to stimulation and contracting to provide movement, and occurs as three major types: skeletal (voluntary) muscle, smooth muscle, and cardiac muscle in the heart. **Nervous tissue** is also excitable, allowing the propagation of electrochemical signals in the form of nerve impulses that communicate between different regions of the body.

The next level of organization is the organ, where several types of tissues come together to form a working unit. Just as knowing the structure and function of cells helps you in your study of tissues, knowledge of tissues will help you understand how organs function.

Tissue Type	Description	Subtypes
Epithelial	line inner and outer surfaces	based on shape (squamous, cuboidal, columnar) and number of layers (simple, stratified, pseudostratified)
Connective	provide structure and connection; characterized by noncellular matrix outside the cells	loose, dense, fibrous, cartilage, bone, blood, adipose
Nervous	coordinate receipt of and response to stimuli	neurons, glial cells
Muscle	movement is a consequence of contraction of these cells results in movement	smooth, striated, cardiac

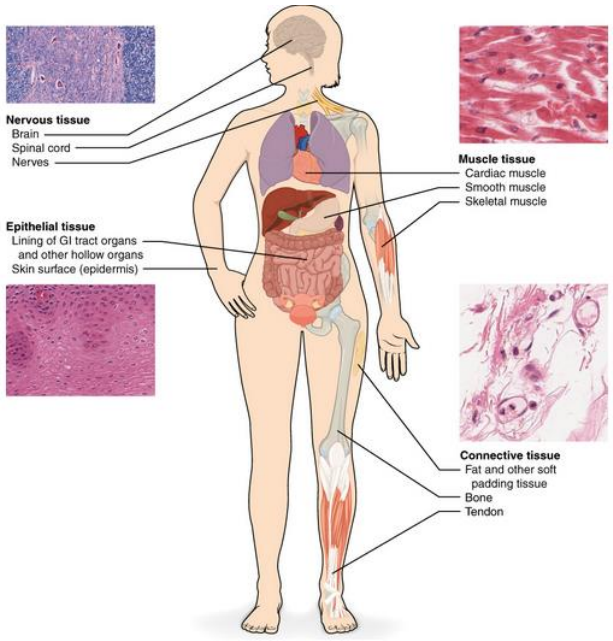

Figure 1. Four Types of Tissue: Body. The four types of tissues are exemplified in nervous tissue, stratified squamous epithelial tissue, cardiac muscle tissue, and connective tissue in small intestine. Clockwise from nervous tissue, LM × 872, LM × 282, LM × 460, LM × 800. (Micrographs provided by the Regents of University of

How do cells form tissues?

The plasma membranes of adjacent cells are usually separated by extracellular fluids that allow transport of nutrients and wastes to and from the bloodstream. In certain tissues, however, the membranes of adjacent cells may join and form a junction. As shown in the figures, three kinds of **cell junctions** are recognized:

- **Desmosomes** are protein attachments between adjacent cells. Inside the plasma membrane, a desmosome bears a disk-shaped structure from which protein fibers extend into the cytoplasm. Desmosomes act like spot welds to hold together tissues that undergo considerable stress (such as skin or heart muscle).
- **Tight junctions** are tightly stitched seams between cells. The junction completely encircles each cell, preventing the movement of material between the cell. Tight junctions are characteristic of cells lining the digestive tract, where materials are required to pass through cells (rather than intercellular spaces) to penetrate the bloodstream.
- **Gap junctions** are narrow tunnels between cells that consist of proteins called connexons. The proteins allow only the passage of ions and small molecules. In this manner, gap junctions allow communication between cells through the exchange of materials or the transmission of electrical impulses.

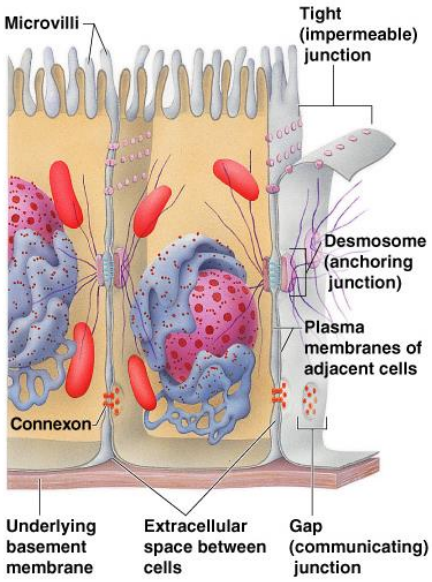

Figure. The three types of cell junctions.

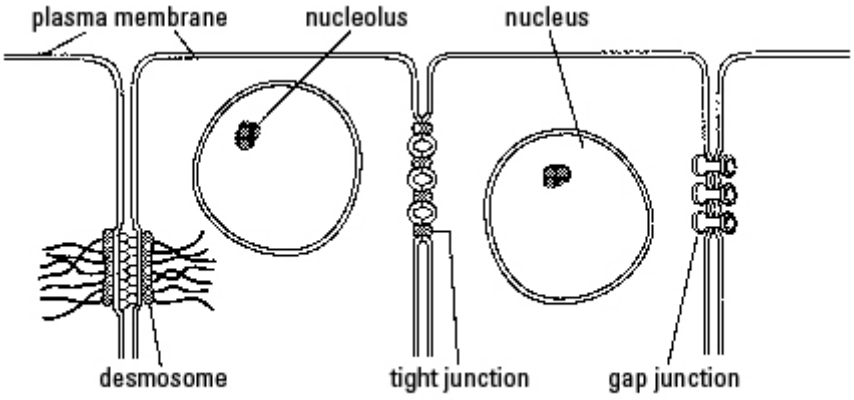

Cell Junctions

- Many times, the plasma membrane has many **microvilli**. Microvilli are finger-like projections that increase surface area for absorption

.

Lesson 2: Epithelial Tissue

Objective:

- Describe the general characteristics and functions of epithelial tissue.
- Determine the relationship between form and function for each type of epithelial tissue.

Epithelial tissue

This tissue is an upper most tissue covering all the organs or body as well as glandular tissue. Its functions are protection, absorption, filtration, and secretion. The cells of this tissue fit closely together. The tissue layer always has one free or exposed surface(**apical**) and a lower surface. This lower **basal surface** is an **o**pposite, deep surface that adheres to an extracellular material attached to a **basement membrane**. **Epithelial tissue** is **avascular** (have no blood supply (and will regenerate easily if well nourished. Classification of the epithelial tissues is based on the type of cell of which the tissue is made, its characteristic shape, and the number of layers of cells. There are three distinctive shapes: **squamous** cells are flat, **cuboidal** cells are cube shaped, and **columnar** cells are tall and narrow. "**Simple**" is the term for a single layer of cells, and "**stratified**" means that many layers of cells are present.

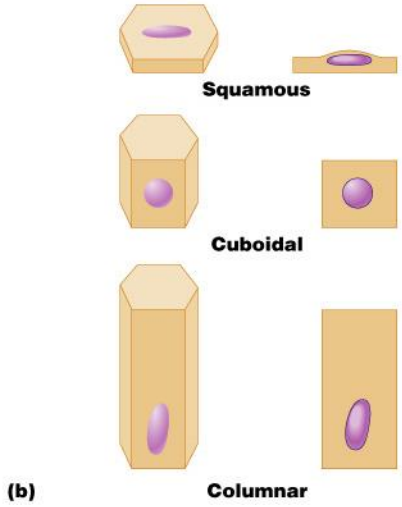

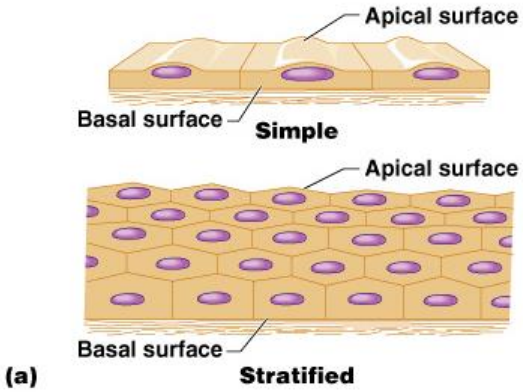

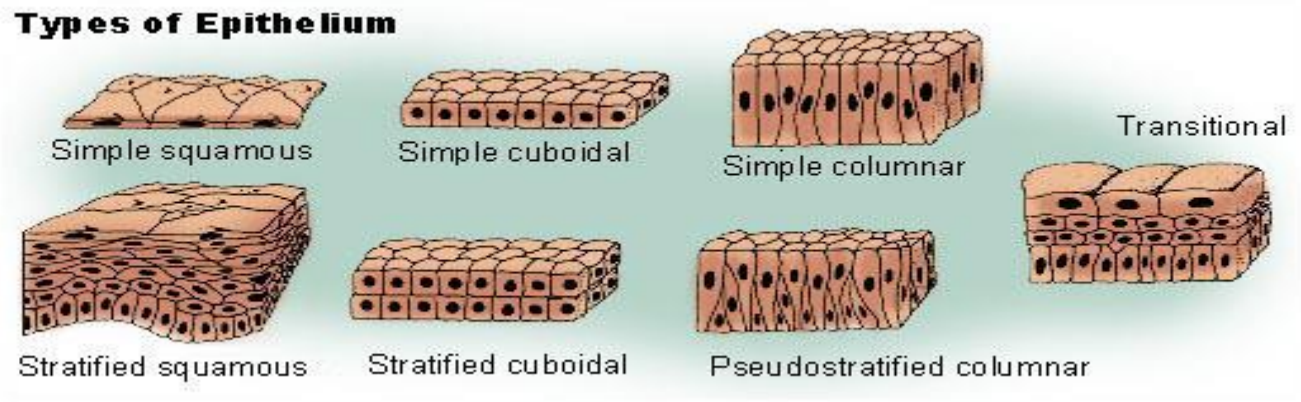

Simple epithelium is one which has a single layer of epithelial cells. It is present at sites where filtration or diffusion of substances is necessary. It is found in the nephron of kidney for filtration of blood, for diffusion of oxygen from lungs to blood. This type of single layer of epithelium is so thin and offers least resistance for transfer of molecules from one side to another.

Based on the shape of cells in this layer, it is further differentiated as simple squamous epithelium, simple cuboidal epithelium and simple columnar epithelium.

Stratified epithelium is a multi-layered epithelium. This is differentiated based on the upper most layer and the shape of cells in bottom layers.

The upper layer cells might be **keratinized**, dehydrated to protect from heat, microbes, wear and tear, chemicals etc. This type of layer is seen in skin. In most other types of stratified epithelium, the upper layer is non-keratinized. Based on the shape of lower layer cells, the epithelium is again differentiated as stratified squamous epithelium, stratified cuboidal epithelium, columnar stratified epithelium and pseudostratified columnar epithelium.

There is another type called **transitional epithelium**. This type of tissue is present in urinary bladder. The cells are cuboidal or columnar in relaxed state. But when there is load, they stretch and become flat to accommodate the substance (urine).

There is one more type of epithelium. It is glandular epithelium which are present in both endocrine and exocrine glands.

<u>Types of simple epithelium tissues:</u>

1. **Simple squamous epithelium:** As the name indicates, this is a single layer of squamous shaped epithelium cells.
    - Usually forms membranes
        - Lines body cavities
        - Lines lungs and capillaries

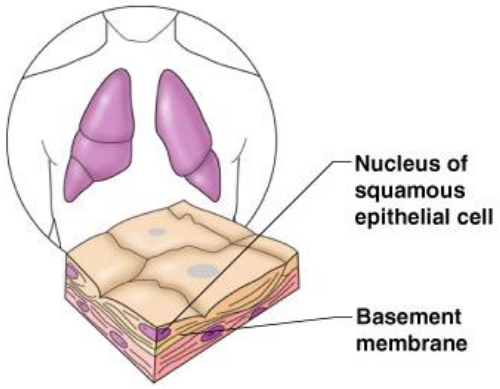

(a) Diagram: Simple squamous

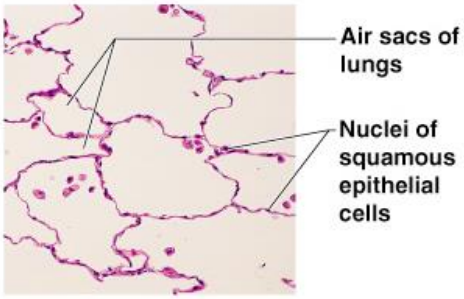

Photomicrograph: Simple squamous epithelium forming part of the alveolar (air sac) walls (400x).

2. **Simple cuboidal epithelium** has single layer of cuboid shaped cells.
    - Common in glands and their ducts
    - Forms walls of kidney tubules
    - Covers the ovaries

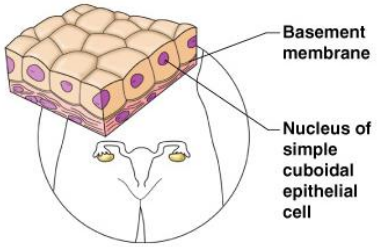

(b) Diagram: Simple cuboidal

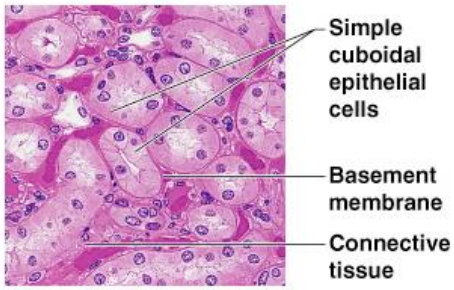

Photomicrograph: Simple cuboidal epithelium in kidney tubules (400x).

3. **Simple columnar epithelium** has single layer of long column shaped cells
    - Often includes goblet cells, which produce mucus
    - Lines digestive tract

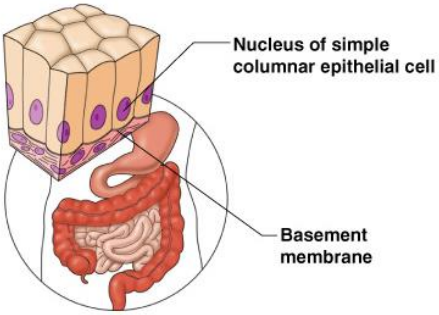

(c) Diagram: Simple columnar

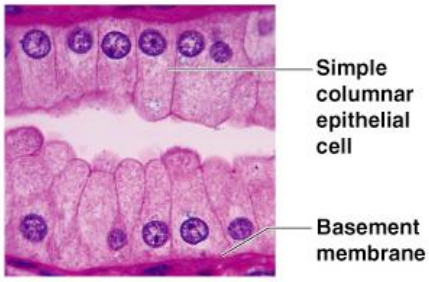

Photomicrograph: Simple columnar epithelium of the stomach lining (1300x).

<u>Types of Stratified epithelium tissues:</u>

1. **Stratified squamous epithelium** has squamous shaped cells arranged in multiple layers.
    - Cells at the free edge are flattened
    - Found as a protective covering where friction is common
    - Locations
        - Skin
        - Mouth
        - Esophagus

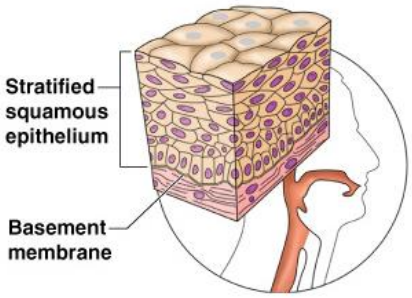

(e) Diagram: Stratified squamous

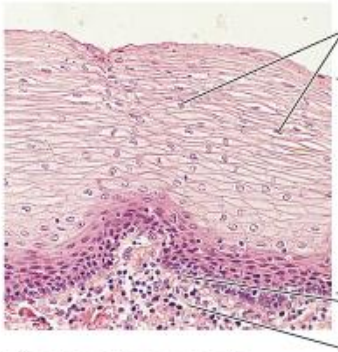

Photomicrograph: Stratified squamous epithelium lining of the esophagus (300x).

2. Stratified cuboidal epithelium has cuboidal cells in multiple layers

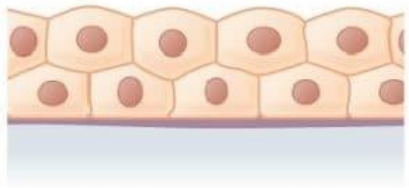

Stratified cuboidal epithelium

3. Stratified columnar epithelium has column shaped cells in layers.

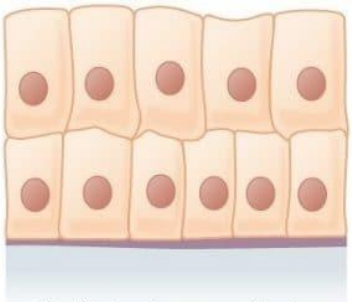

Stratified columnar epithelium

4. Pseudo-stratified columnar epithelium: Single layer of columnar shaped cells arranged in such a way to give false impression of multiplayer.

- Single layer, but some cells are shorter than others
- Often looks like a double cell layer
- Sometimes ciliated, such as in the respiratory tract
- May function in absorption or secretion

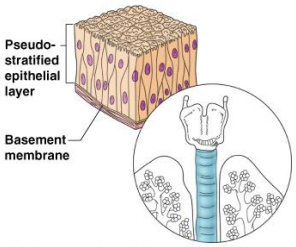

(d) Diagram: Pseudostratified (ciliated) columnar

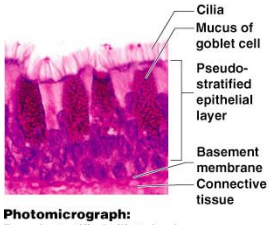

Photomicrograph: Pseudostratified ciliated columnar epithelium lining the human trachea (400x).

5**. Transitional epithelium. Transitional epithelium** is a type of stratified epithelium in which the surface cells change shape from round to squamous.

- Shape of cells depends upon the amount of stretching
- Lines organs of the urinary system

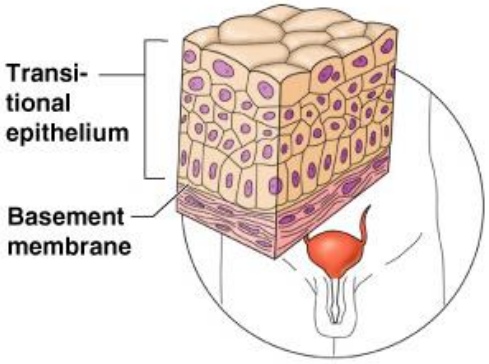

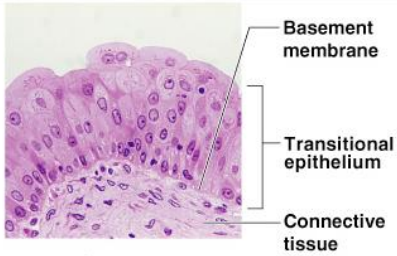

Photomicrograph:
Transitional epithelium lining of the bladder, relaxed state (500x); note the bulbous, or rounded, appearance of the cells at the surface; these cells flatten and become elongated when the bladder is filled with urine.

<u>Glandular Epithelium</u>

Glands are cells or organs that secrete something; that is, they produce a substance that has a function either at that site or at a more distant site.

Unicellular means "one cell." Goblet cells are an example of unicellular glands. As mentioned earlier, goblet cells are found in the lining of the respiratory and digestive tracts. Their secretion is mucus. Most glands are made of many similar cells, or of a variety of cells with their secretions mingled into a collective secretion. **Multicellular** glands may be divided into two major groups: exocrine glands and endocrine glands. **Exocrine glands** have **ducts** (tubes) to take the secretion away from the gland to the site of its function. Often **cuboidal cells** lining ducts that empty onto surface of covering and lining epithelium Salivary glands, for example, secrete saliva that is carried by ducts to the oral cavity. Sweat glands secrete sweat that is transported by ducts to the skin surface, where it can be evaporated by excess body heat. The gastric glands of the stomach lining contain different kinds of cells (see Fig. 16–5), which produce hydrochloric acid and the enzyme pepsin. Both secretions are part of gastric juice. **Endocrine glands** are ductless glands. The secretions of endocrine glands are a group of chemicals called **hormones**, which enter capillaries and are circulated throughout the body. Often **cuboidal cells** inside gland secrete to interstitial fluid. Hormones then bring about specific effects in their target organs. These effects include aspects of growth, use of minerals and other nutrients, and regulation of blood pressure, and will be covered in more detail later in the course. Examples of endocrine glands are the thyroid gland, adrenal glands, and pituitary gland.

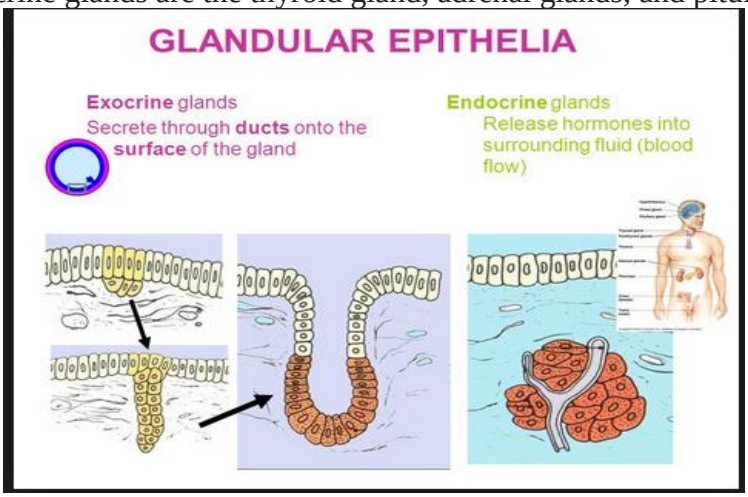

Table 4–1 TYPES OF EPITHELIAL TISSUE

Type	Structure	Location and Function
Simple squamous	One layer of flat cells	• Alveoli of the lungs—thin to permit diffusion of gases • Capillaries—thin to permit exchanges of materials; smooth to prevent abnormal blood clotting
Stratified squamous	Many layers of cells; surface cells flat; lower cells rounded; lower layer undergoes mitosis	• Epidermis—surface cells are dead; a barrier to pathogens • Lining of esophagus, vagina—surface cells are living; a barrier to pathogens
Transitional	Many layers of cells; surface cells change from rounded to flat	• Lining of urinary bladder—permits expansion without tearing the lining
Cuboidal	One layer of cube-shaped cells	• Thyroid gland—secretes thyroxine • Salivary glands—secrete saliva • Kidney tubules—permit reabsorption of useful materials back to the blood
Columnar	One layer of column-shaped cells	• Lining of stomach—secretes gastric juice • Lining of small intestine—secretes enzymes and absorbs end products of digestion (microvilli present)
Ciliated	One layer of columnar cells with cilia on their free surfaces	• Lining of trachea—sweeps mucus and dust to the pharynx • Lining of fallopian tube—sweeps ovum toward uterus

Lesson 3: Connective Tissue

Objective:

- Describe the general characteristics and functions of connective tissue.
- Determine the relationship between form and function for each type of connective tissue.

Connective tissues as the name indicates, is in a connecting position in between tissues. There are many types including things like adipose tissues and reticular tissue.

This connective tissue is divided as

1. Loose connective tissue. (Areolar tissue, adipose tissue)
2. Dense connective tissue.
3. Cartilage tissue
4. Bone tissue
5. Liquid connective tissue (examples of tissue is blood, WBC's, lymph)



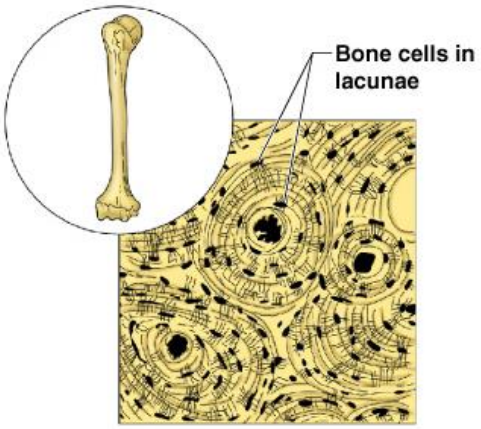

(a) Diagram: Bone

Connective Tissue is found everywhere in the body and includes the most abundant and widely distributed tissues. It binds body tissues together, supports the body, and provides protection. Some tissue types are well vascularized while some have poor blood supply or are avascular. The cells of **connective tissue** are embedded in a great amount of **extracellular** material. **Extracellular matrix** is non-living material that surrounds living cells. It is made of two main elements. This matrix is secreted by the cells. It consists of protein fibers (**collagen fibers, elastic fibers and reticular fibers**) embedded in an amorphous mixture of huge protein-polysaccharide ("proteoglycan") molecules. This amorphous mixture (**Ground substance)** is mostly water along with adhesion proteins and polysaccharide molecules. Fibers are also produced by the cells.

Connective Tissue Types

Bone (osseous tissue) is composed of Bone cells in lacunae (cavities), hard matrix of calcium salts and large numbers of collagen fibers. Its function is to protect and support the body.

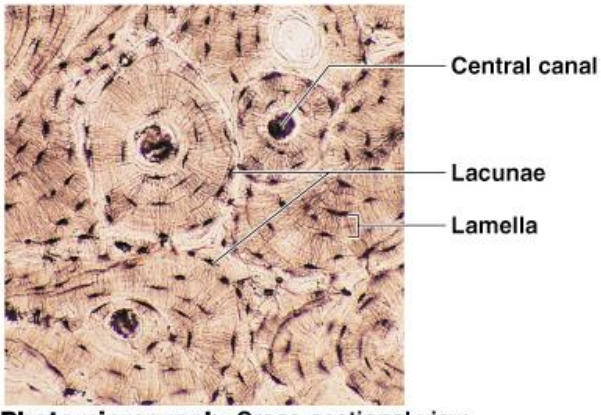

Photomicrograph: Cross-sectional view of ground bone (70x).

Hyaline cartilage is the most common cartilage and is composed of collagen fibers and a rubbery matrix. The entire fetal skeleton is hyaline cartilage.

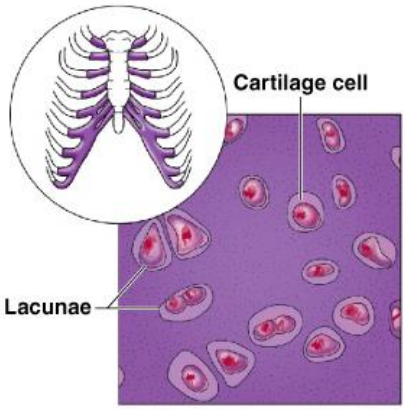

(b) Diagram: Hyaline cartilage

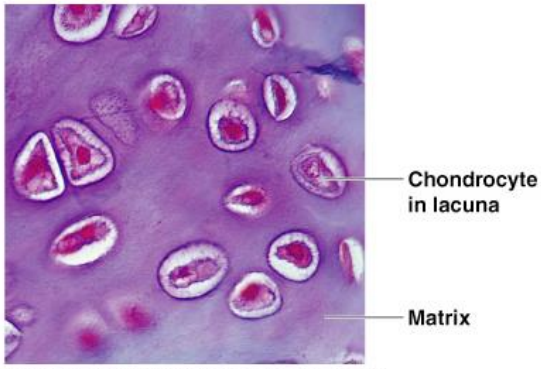

Photomicrograph: Hyaline cartilage from the trachea (300x).

Elastic cartilage or yellow **cartilage** is a type of **cartilage** present in the outer ear, Eustachian tube and epiglottis. It contains **elastic** fiber networks and collagen type II fibers. The principal protein is elastin. Elastic cartilage provides elasticity and support.

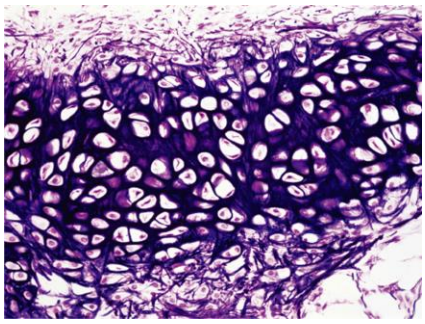

Fibrocartilage is highly compressible and forms cushion-like discs between vertebrae.

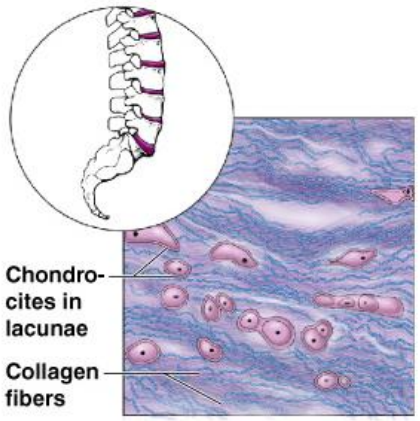

(c) Diagram: Fibrocartilage

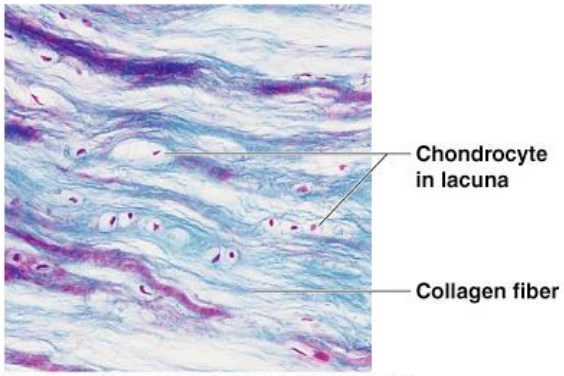

Photomicrograph: Fibrocartilage of an intervertebral disc (200x).

Dense connective tissue is the main matrix element is collagen fibers. The cells that make it are called fibroblasts. They include **tendons** (attach muscle to bone) and **ligaments** (attach bone to bone).

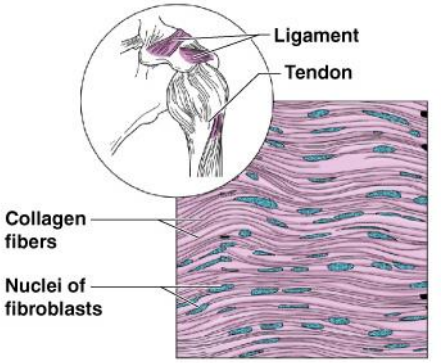

(d) Diagram: Dense fibrous

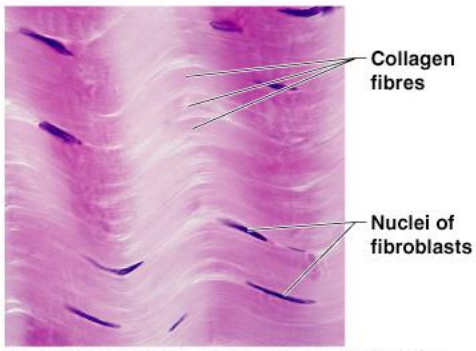

Photomicrograph: Dense fibrous connective tissue from a tendon (1000x).

Areolar connective tissue is the most widely distributed connective tissue. It is soft, pliable tissue containing all fiber types. It can also soak up excess fluid.

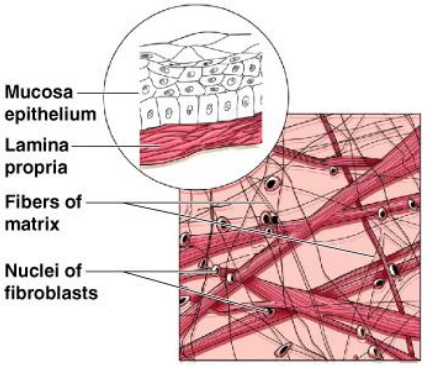

(e) Diagram: Areolar

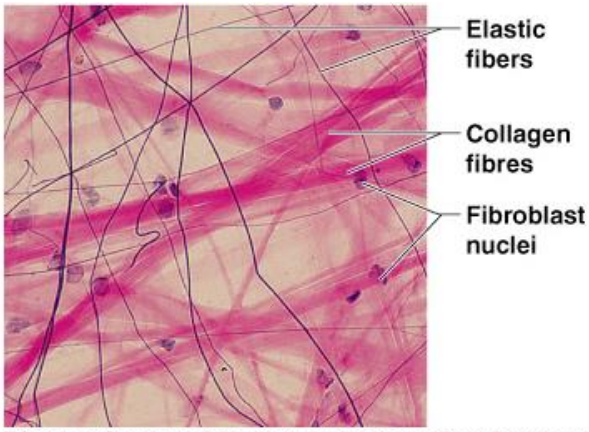

Photomicrograph: Areolar connective tissue, a soft packaging tissue of the body (400x).

Adipose tissue is a matrix of areolar tissue in which fat globules predominate. Many cells contain large lipid deposits that function to insulate the body, protect some organs and serve as a site of fuel storage.

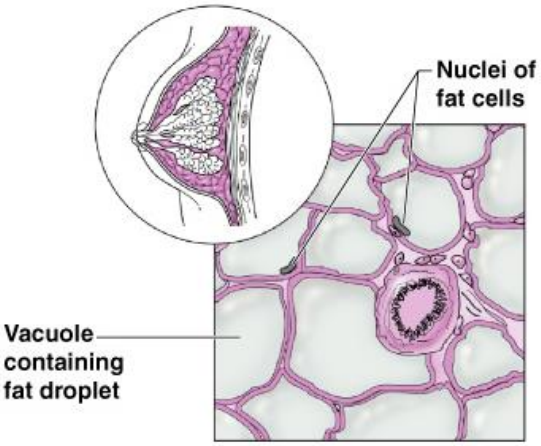

(f) Diagram: Adipose

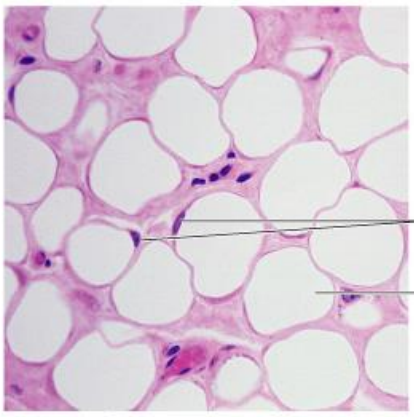

Photomicrograph: Adipose tissue from the subcutaneous layer beneath the skin (600x).

Reticular connective tissue is a **d**elicate network of interwoven fibers that forms a **stroma** (internal supporting network) of lymphoid organs. Included structures are the **lymph nodes**, **spleen** and **bone marrow.**

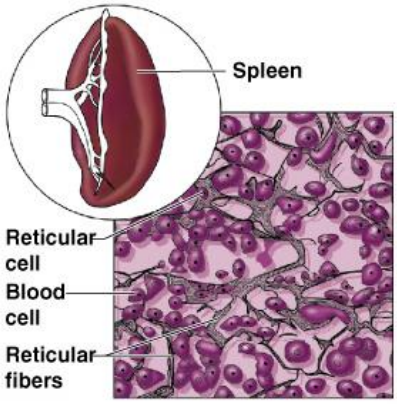

(g) Diagram: Reticular

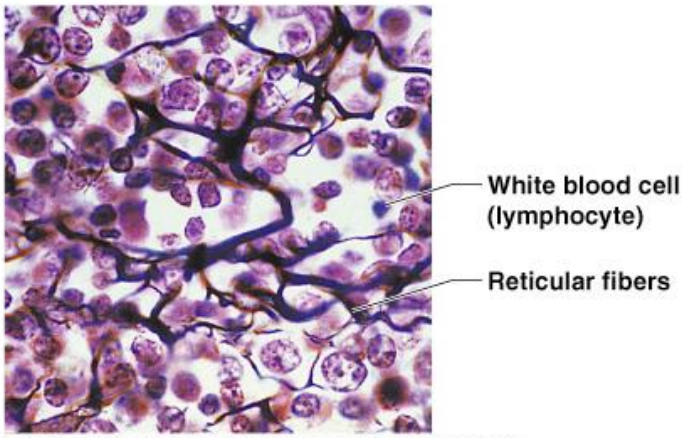

Photomicrograph: Dark-staining network of reticular connective tissue (350x).

Blood is a connective tissue in which blood cells surrounded by fluid matrix. The fibers are visible during clotting. It functions as the transport vehicle for materials

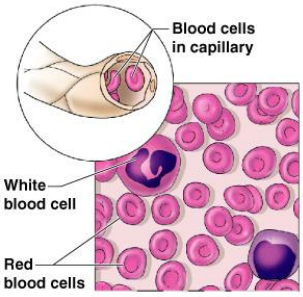

(h) Diagram: Blood

Lesson

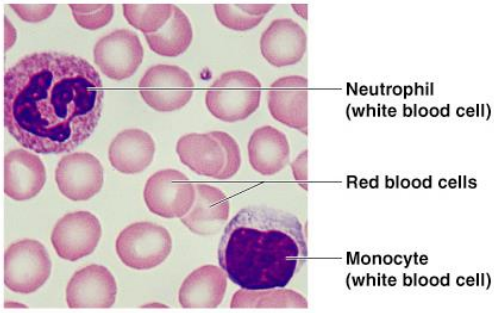

Photomicrograph: Smear of human blood (1500x); two white blood cells are seen among the red blood cells.

Lesson 4: Muscular Tissue

Objective:

- Describe the general characteristics and functions of muscular tissue.
- Determine the relationship between form and function for each type of muscular tissue.

Muscular tissue as the name indicates, makes the muscles of the body. Muscle tissue is characterized by properties that allow movement. Muscle cells are excitable; they respond to a stimulus. They are contractile, meaning they can shorten and generate a pulling force. When attached between two movable objects, in other words, bones, contractions of the muscles cause the bones to move. Some muscle movement is **voluntary**, which means it is under conscious control. For example, a person decides to open a book and read a chapter on anatomy. Other movements are **involuntary**, meaning they are not under conscious control, such as the contraction of your pupil in bright light. Muscle tissue is classified into three types according to structure and function:

- Skeletal muscle tissue
- Cardiac tissue
- Smooth muscle tissue

Skeletal muscle is attached to bones and its contraction makes possible locomotion, facial expressions, posture, and other voluntary movements of the body. Forty percent of your body mass is made up of skeletal muscle. Skeletal muscles generate heat as a byproduct of their contraction and thus participate in **thermal homeostasis**. Shivering is an involuntary contraction of skeletal muscles in response to perceived lower than normal body temperature. The muscle cell, is called a **myocyte** and their numbers remain relatively constant throughout life. Skeletal muscle tissue is arranged in bundles surrounded by connective tissue. Under the light microscope, muscle cells appear striated with many nuclei squeezed along the membranes. The **striation** is due to the regular alternation of the contractile proteins **actin** and **myosin**, along with the structural proteins that couple the contractile proteins to connective tissues. The cells are **multinucleated** because of the fusion of the many myoblasts that fuse to form each long muscle fiber.

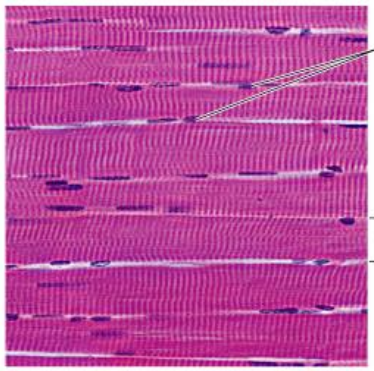

Photomicrograph: Skeletal muscle (approx. 300x).

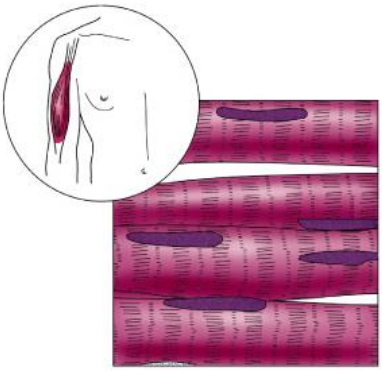

(a) Diagram: Skeletal muscle

Cardiac muscle forms the contractile walls of the heart. The cells of cardiac muscle, known as **cardiomyocytes**, also appear **striated** under the microscope. Unlike skeletal muscle fibers, cardiomyocytes are single cells typically with a single centrally located **nucleus.** A principal characteristic of cardiomyocytes is that they **contract on their own** intrinsic rhythms without any external stimulation. Cardiomyocyte attach to one another with specialized cell junctions called **intercalated discs**. Intercalated discs have both anchoring junctions and gap junctions. Attached cells form long, branching cardiac muscle fibers that are, essentially, a mechanical and electrochemical syncytium allowing the cells to **synchronize** their actions. The cardiac muscle pumps blood through the body and is under **involuntary control**. The attachment junctions hold adjacent cells together across the dynamic pressures changes of the cardiac cycle.

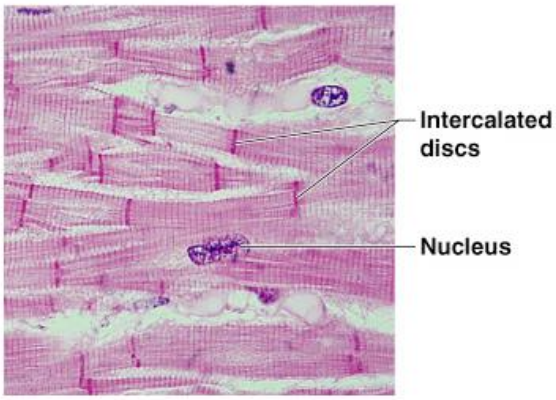

Photomicrograph: Cardiac muscle (800x).

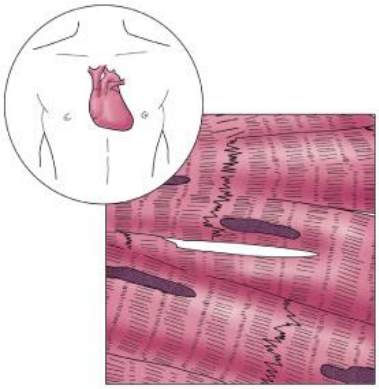

(b) Diagram: Cardiac muscle

Smooth muscles are spindle or cone shaped in structure. They help in contraction and relaxation of many organs like lungs, stomach, uterus etc. and tend to surround hollow organs. They help in movement, contraction and other physiological activities. They are involuntary in nature. They are controlled by brain. There are no visible striations and one nucleus per cell.

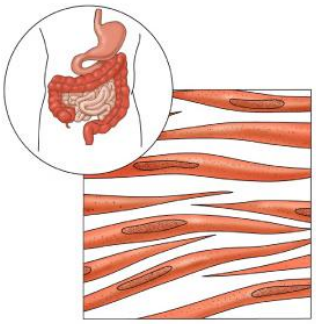

(c) Diagram: Smooth muscle

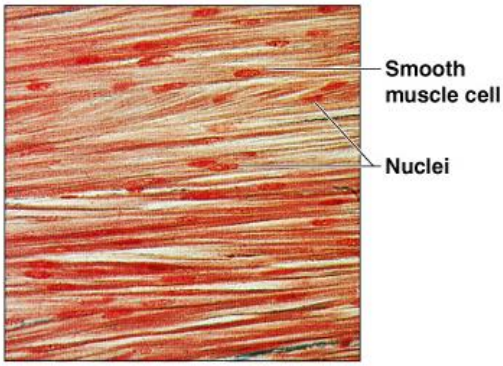

Photomicrograph: Sheet of smooth muscle (approx. 600x).

Lesson 5: Nervous Tissue

Objective:

- Describe the general characteristics and functions of nervous tissue.
- Determine the relationship between form and function of nervous tissue.
- Discuss how nervous tissue mediates perception and response

Nervous tissue is mostly present in the entire **nervous system** including brain and spinal cord. It has two types of tissue as **nervous cell** and **neuroglia**.

The **nerve cells** are the longest cells in the body. They can be up to few meters. They transmit **impulses** from brain to other body parts and vice-verse. This tissue controls the whole body by conduction of impulses across the body. The tissue operates by use of bio-molecular chemical substances called as **neurotransmitters.**

Two main classes of cells make up nervous tissue: the **neuron** and **neuroglia**. **Neurons** propagate information via electrochemical impulses, called **action potentials**, which are biochemically linked to the release of chemical signals. **Neuroglia** play an essential role in supporting neurons

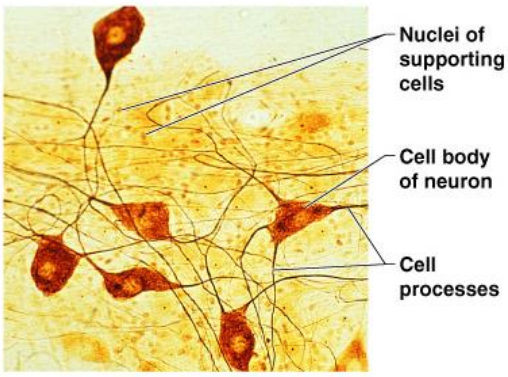

Photomicrograph: Neurons (100x)

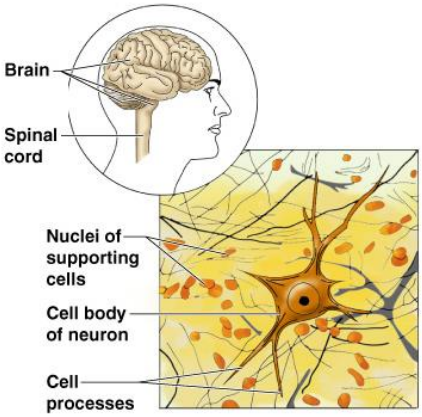

Diagram: Nervous tissue

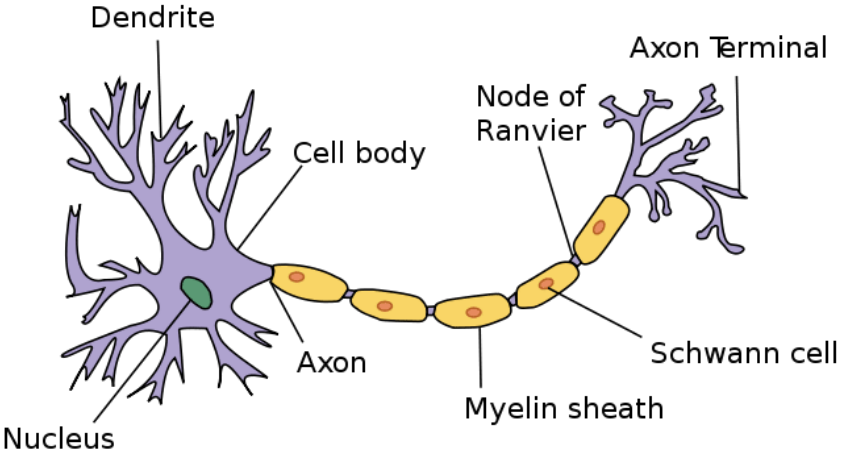

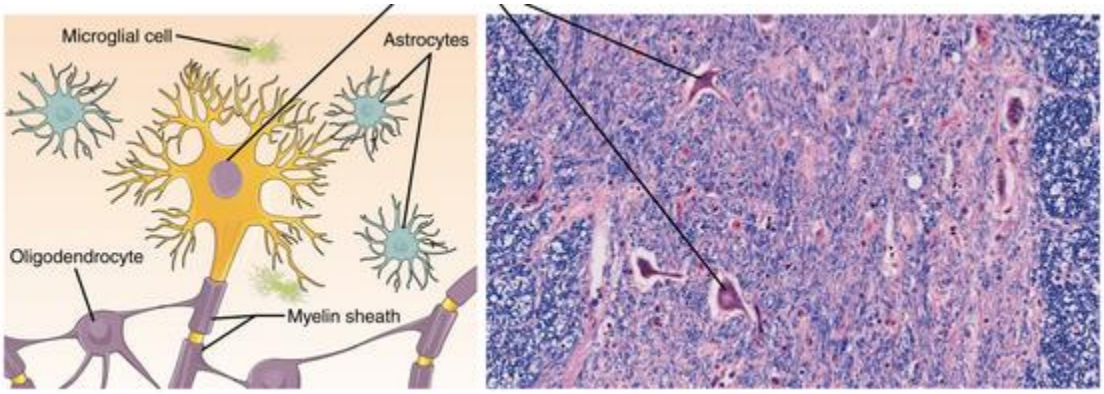

Neurons display distinctive morphology, well suited to their role as conducting cells, with three main parts. The cell body includes most of the cytoplasm, the organelles, and the nucleus. **Dendrites** branch off the cell body and appear as thin extensions. A long "tail," the **axon**, extends from the **neuron body** and can be wrapped in an insulating layer known as **myelin**, which is formed by accessory cells. The **synapse** is the gap between nerve cells, or between a nerve cell and its target, for example, a muscle or a gland, across which the **impulse** is transmitted by chemical compounds known as neurotransmitters. When a neuron is sufficiently stimulated, it generates an **action potential** that propagates down the axon towards the synapse. If enough neurotransmitters are released at the synapse to stimulate the next neuron or target, a response is generated.

The second class of neural cells comprises the **neuroglia or glial cells**, which have been characterized as having a simple support role. The word "glia" comes from the Greek word for glue. Recent research is shedding light on the more complex role of neuroglia in the function of the brain and nervous system. **Astrocyte** cells, named for their distinctive star shape, are abundant in the central nervous system. The astrocytes have many functions, including regulation of ion concentration in the intercellular space, uptake and/or breakdown of some neurotransmitters, and formation of the blood-brain barrier, the membrane that separates the circulatory system from the brain. **Microglia** protect the nervous system against infection but are not nervous tissue because they are related to macrophages. **Oligodendrocyte** cells produce myelin in the central nervous system (brain and spinal cord) while the **Schwann cell** produces myelin in the peripheral nervous system

Lesson 6: Tissue Repair

Objective:

- List the body's response to tissue injury
- Explain the process of tissue repair

Tissues of all types are vulnerable to injury and, inevitably, aging. In the former case, understanding how tissues respond to damage can guide strategies to aid repair. In the latter case, understanding the impact of aging can help in the search for ways to diminish its effects.

Tissue Injury and Repair

Inflammation is the standard, initial response of the body to injury. Whether biological, chemical, physical, or radiation burns, all injuries lead to the same sequence of physiological events. Inflammation limits the extent of injury, partially or fully eliminates the cause of injury, and initiates repair and regeneration of damaged tissue. **Necrosis**, or accidental cell death, causes inflammation. **Apoptosis** is programmed cell death, a normal step-by-step process that destroys cells no longer needed by the body. By mechanisms still under investigation, apoptosis does not initiate the inflammatory response. Acute inflammation resolves over time by the healing of tissue. If inflammation persists, it becomes chronic and leads to diseased conditions. Arthritis and tuberculosis are examples of chronic inflammation. The suffix **"-itis" denotes inflammation** of a specific organ or type, for example, peritonitis is the inflammation of the peritoneum, and meningitis refers to the inflammation of the meninges, the tough membranes that surround the central nervous system

Upon tissue injury, damaged cells release inflammatory chemical signals that evoke local **vasodilation**, the widening of the blood vessels. Increased blood flow results in apparent redness and heat. In response to injury, **mast cells** present in tissue degranulate, releasing the potent vasodilator **histamine**. Increased blood flow and inflammatory mediators recruit white blood cells to the site of inflammation. The endothelium lining the local blood vessel becomes "leaky" under the influence of histamine and other inflammatory mediators allowing neutrophils, macrophages, and fluid to move from the blood into the interstitial tissue spaces. The excess liquid in tissue causes swelling, more properly called **edema.** The swollen tissues squeezing pain receptors cause the sensation of pain. **Prostaglandins** released from injured cells also activate pain neurons. Non-steroidal anti-inflammatory drugs (NSAIDs) reduce pain because they inhibit the synthesis of prostaglandins. High levels of NSAIDs reduce inflammation. Antihistamines decrease allergies by blocking histamine receptors and as a result the histamine response.

After containment of an injury, the tissue repair phase starts with removal of toxins and waste products. **Clotting** (coagulation) reduces blood loss from damaged blood vessels and forms a network of fibrin proteins that trap blood cells and bind the edges of the wound together. A scab forms when the clot dries, reducing the risk of infection. Sometimes a mixture of dead leukocytes and fluid called **pus** accumulates in the wound. As healing progresses, **fibroblasts** from the surrounding connective tissues replace the collagen and extracellular material lost by the injury. **Angiogenesis,** the growth of new blood vessels, results in vascularization of the new tissue known as **granulation tissue**. The clot retracts pulling the edges of the wound together, and it slowly dissolves as the tissue is repaired. When a large amount of granulation tissue forms and capillaries disappear, a pale scar is often visible in the healed area. A **primary union** describes the healing of a wound where the edges are close together. When there is a gaping wound, it takes longer to refill the area with cells and collagen. The process called **secondary union** occurs as the edges of the wound are pulled together by what is called **wound contraction**. When a wound is more than one quarter of an inch deep, sutures (stitches) are recommended to

promote a primary union and avoid the formation of a disfiguring scar. Regeneration is the addition of new cells of the same type as the ones that were injured.